

A Successful Replacement of Ascending Aorta and Aortic Valve With a composite Graft

Kyung Soo Cho, M.D.*, Won Gon Kim, M.D.*, Kyu Seok Cho, M.D.*,
Joo Chul Park, M.D.* and Seh Young Yoo, M.D.*

< 국문초록 >

대동맥판막 및 상행대동맥 대치이식술 1예 - Bentall씨 수술 변형술 -

조경수·김원곤·조규석·박주철·유세영

대동맥판막 폐쇄부전증을 동반한 상행대동맥류의 수술 방법은 여러가지 보고되어 왔으나 최근 Cabrol 등은 Modified Bentall operation을 시행하여 좋은 결과를 보고하고 있다.

경희대학교 흉부외과에서는 48세된 여자 환자에서 체외 순환하에 대동맥판막 폐쇄부전증을 동반한 상행대동맥류 1예를 Bentall씨 수술 변형술 시행하여 성공적으로 수술 치험 하였기에 보고하는 바이다.

환자는 입원시 수개월에 걸친 운동시 호흡곤란과 좌측 상지 및 견갑부의 방사선통을 호소하였다. 이학적 및 심초음파 검사와 대동맥 조영촬영술등으로 대동맥판막 폐쇄부전증을 동반한 상행대동맥류를 확진할 수 있었다. 수술은 상행대동맥과 대동맥판막을 27 mm St. Jude인공판막을 내재한 이식편으로 대치시키며 양측 관상동맥을 중간 인조혈관을 사용하여 별도로 문합시켜 주었다. 이후 문합부의 출혈을 방지하기 위해 우심방 부속기와 대동맥류 벽 사이에 누공을 만들어 주었다.

환자는 별다른 문제없이 퇴원하였으며 현재 14개월째 혈액학적으로 양호한 상태에서 외래 추적 관찰 중이다.

- Abstract -

A forty-eight-year-old female patient with ascending aortic aneurysm with aortic insufficiency underwent a modified Bentall operation.

The ascending aorta and the aortic valve were replaced with a composite graft containing a St. Jude valve.

The coronary orifices were anastomosed to the tubular Dacron prosthesis by means of a second smaller Gore-tex tube, and a fistula between the aneurysmal sac and the right atrial appendage was created to drain oozing from the prosthesis.

The postoperative course was uneventful and the patient was discharged without complication.

She is doing well on the 14 months follow-up.

* 경희대학교 의과대학 흉부외과학교실

* Department of Thoracic and Cardiovascular Surgery, College of Medicine, Kyung Hee University
1989년 7월 28일 접수

Introduction

Although great progress has been made in the surgical management of ascending aortic aneurysm with aortic insufficiency, the ascending aorta is still challenging, and questions remain as to the best mode of operation.

Total replacement of the ascending aorta with reimplantation of the coronary arteries expands the possibilities for definitive surgical treatment of ascending aortic aneurysms with associated aortic insufficiency.

Bentall H H, et al²⁾. reported the first use of a tubular Teflon graft sutured to a valve prosthesis as one unit for the replacement of the ascending aorta and aortic valve.

This technique however, with all of its advantages, carries a certain risk of bleeding at the level of the suture line for reimplantation of the coronary arteries, difficult to anastomosis, and excessive traction of anastomosis site.

To eliminate these risks, Cabrol reported^{3~5)}, a variant of the technique utilizing a Cacron tube connecting the coronary orifices to the composite graft.

An ascending aortic aneurysm with aortic insufficiency treated successfully by a modified Bentall's operation is described, and problems of the related surgical procedures are discussed with a review of the literature.

Case of Report

A 48-year-old female patient was admitted to this hospital on April 27, 1988, for the evaluation of exertional dyspnea and radiating pain on the left shoulder and the left upper extremity.

She had neither evidence of Marfan's syndrome, nor the past medical history related to syphilis or chest trauma.

Blood pressure was 200/80 mmhg with heart rate of 102 beats per minute with irregular rhythm.

Respiratory rate was 20/min.

A decrescendo diastolic murmur was heard in the right sternal border.

The electrocardiogram revealed ST depression, T wave inversion in II, III, aVF, V4, 5, 6, and atrial fibrillation.

Chest roentgenogram demonstrated remarkable cardiomegaly and a small amount of pleural effusion on the right lung field (Fig. 1).

An echocardiogram revealed an aneurysm on the proximal ascending aorta, left ventricular enlargement and severe aortic regurgitation (Fig. 2).

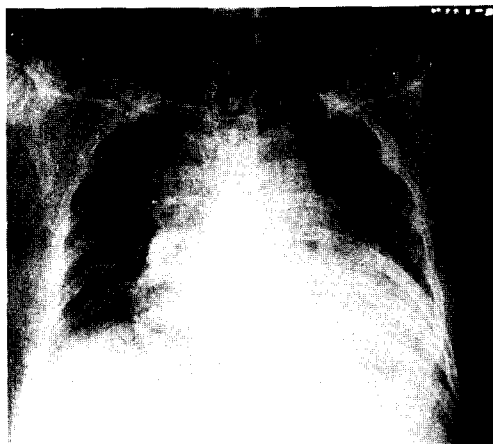

Fig. 1. Roentgenogram of chest at admission.

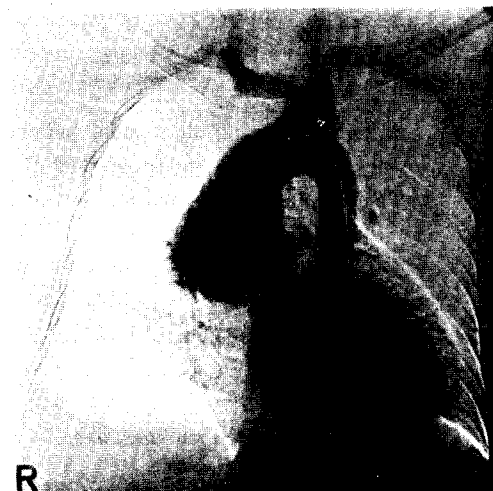

Fig. 2. Preoperative angiogram of the ascending aortic aneurysm.

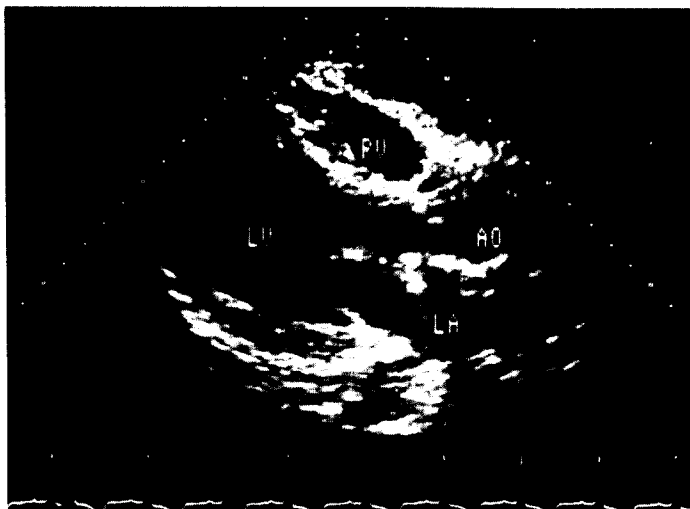

Fig. 3. Preoperative echocardiogram.

The aortogram confirmed the presence of ascending aortic aneurysm with grade IV aortic regurgitation, showing no definitive intimal flap(Fig. 3).

After systemic heparinization, extracorporeal circulation was established via femoral a. and venae cavae.

The aorta was cross-clamped just below the brachiocephalic arteries.

The aneurysm was opened longitudinally and the edges were suspended by traction sutures on either side.

There was marked fusiform dilatation of the sinuses of Valsalva as well as the aortic annulus with upward displacement of coronary ostia in the operative field. Myocardial protection was continued by pericardial ice water irrigation and intermittent infusion of cardio-plegic solution directly into both coronary ostia.

After the examination of the lesions of the aortic wall and the aortic valve, the latter was excised.

A 30 mm Dacron composite graft containing a 27 mm St. Jude valve was chosen, and preclotted with a waiting donor's fresh blood which was drawn immediately after choosing the prosthesis.

The end bearing the St. Jude valve was sutured to the aortic annulus with interrupted mattress su-

tures of 3.0 prolene with pledgets.

The two coronary ostia were then anastomosed to the ends of an intermediary tube, Gore-tex, 8 mm in diameter.

The connection to the left coronary ostium was established initially and the intermediary tube was led circumferentially around the right flank of the aortic prosthesis anteriorly to where it was anastomosed to the right coronary ostium.

The distal end of the aortic prosthesis was sewn to the inferior of the aneurysmal sac just below the origin of the brachiocephalic trunk with interrupted mattress sutures of 2.0 prolene with pledgets.

The aortic clamp was temporarily released and complete hemostasis of the suture line was confirmed.

The aorta was then reclamped and coronary tube was connected to the aortic tube with a side to side anastomosis(Fig. 4).

The periprosthetic space was drained into the right atrium, creating about 1 cm fistula between the space and the right atrial appendage(Fig. 5).

The postoperative course was uneventful and postoperative hemodynamic data were within normal ranges.

She was discharged with no complications. Four-

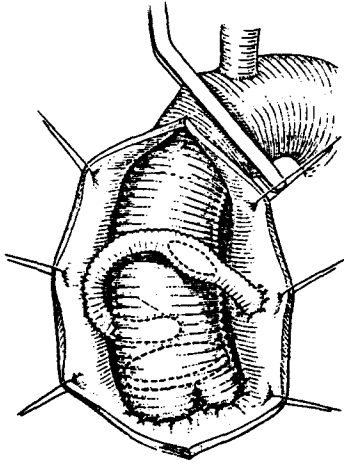


Fig. 4. Tubular prosthesis with St. Jude valve plus intermediate tube anastomosed to the orifices of the coronary arteries.

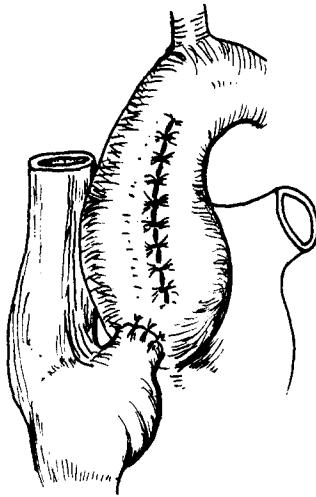


Fig. 5. Shunt from aneurysmal sac to right atrium.

teen months postoperatively, the patient is in good hemodynamic condition.

Discussion

Over the years, various methods of dealing with the still formidable problem of aortic insufficiency associated with ascending aortic aneurysms have been described.

Initial efforts were aimed at preventing rupture

of the aneurysm by aneurysmorrhaphy, with hope that reduction in aortic size would ameliorate the aortic regurgitation¹⁾. Muller and associates reported⁹⁾ successful aneurysmorrhaphy combined with a direct plastic repair of the aortic valve.

However, Merendino's group reported⁸⁾ disastrous results with this approach, especially in patients with Marfan's syndrome.

Ferlic et al reported⁶⁾ a partial circumferential or cuneiform resection of the ascending aorta followed by direct anastomosis with a Woven prosthetic graft carried a relatively high mortality because of tearing of fragile aortic wall with resultant rupture or acute dissection.

In 1964, Wheat, et al reported¹⁰⁾ the resection of the ascending aorta leaving the sinuses of Valsalva in place and utilizing a Dacron prosthesis for reestablishment of continuity.

This is a logical technique if the sinuses of Valsalva are uninvolved.

But, if the failure to excise the sinuses of Valsalva, the residual tissue is weak and the anastomosis is fragile.

At long term, the aneurysmal zone is subject to compression, dissection, and rupture.

In 1968, Bentall and De Bono reported²⁾ the use of a composite graft as one unit for the replacement of the ascending aorta and aortic valve.

But, the delicate portion of his technique is the reimplantation of the coronary orifices on the prosthetic aortic tube.

The suturing is difficult because of imperfect visibility, fragile aortic tissue, traction on the aortic wall at the level of the reimplanted ostia and becomes the source of hemorrhage, which is difficult to control because of inaccessibility.⁷⁾

These same mechanisms have been blamed for the occurrence of false aneurysms demonstrated later at the zone of reimplantation.

In order to avoid these complications, Cabrol and associates³⁻⁵⁾, lead to employ an intermediate Dacron tube, construct an easy anastomosis without tension and with satisfactory hemostasis and

the large width of the side to side anastomosis between the two prosthetic tubes provides what amounts of a separate insertion of the two coronary orifices and thereby avoids the late risk of a single coronary ostium.

We experienced one case of ascending aortic aneurysm with aortic insufficiency who was treated successfully by a modified Bentall operation.

This technique provided very satisfactory early result.

REFERENCES

1. Bahnson HT, Nelson AR: *Cystic medial necrosis as a cause of localized aortic aneurysms amenable to surgical treatment. Ann Surg 144:519-520, 1956*
2. Bentall HH, De Bono A: *A technique for complete replacement of the ascending aorta. Thorax 23:338, 1968*
3. Cabrol C, Gandjbakhch I, Cham B: *Replacement total avec reimplantation des arteres coronaires. Nouv Presse Med 7:363-365, 1978*
4. Cabrol C, Pavie A, Gandjbakhch I, Vailemont JP, Guiraudon G, Laughlin L, Etievent P, Cham B: *Complete replacement of the ascending aorta with reimplantation of the coronary arteries. New surgical approach. J Thorac Cardiovasc Surg 81:309-315, 1981*
5. Cabrol C, Pavie A, Mesnildrey P, Gandjbakhch I, Laughlin L, Bors V, Corcos T, Grondin P: *Long-term results with total replacement of the ascending aorta and reimplantation of the coronary arteries. J Thorac Cardiovasc Surg 91:17, 1986*
6. Ferlic RM, Goott B, Edwards E, Lillehei CW: *Aortic valvular insufficiency associated with cystic medial necrosis. Ann Surg 165:1, 1967*
7. Mayer JE, Lindsay WG, Wang Y, Jorgensen CR, Nicollogg DM: *Complsite replacement of the aortic valve with ascending aorta. J Thorac Cardiovasc Surg 76:816, 1978*
8. Merendino KA, Winterscheid LC, Dillard DH: *Cystic medial necrosis with and without Marfans syndrome Surg Clin North Am 47:1403, 1967*
9. Muller WH, Dammann JF, Warren WG: *Surgical correction of cardio-vascular deformities in Marfans syndrome. Ann Surg 152:506, 1960*
10. Wheat MW, jr, Bartley TD: *Successful replacement of the entire ascending aorta and aortic valve: J Am Med Asso 188:717, 1964*