

## Evaluation of Enzyme-linked Immunosorbent Assay in Serological Diagnosis of Human Neurocysticercosis using paired Samples of Serum and Cerebrospinal Fluid\*

Seung-Yull Cho<sup>1</sup>, Suk-Il Kim<sup>1</sup>, Shin-Yong Kang<sup>1</sup>, Duck Young Choi<sup>2</sup>, Jong Sik Suk<sup>2</sup>, Kil Soo Choi<sup>3</sup>, Young Soo Ha<sup>4</sup>, Chin Sang Chung<sup>5</sup> and Hojin Myung<sup>5</sup>

<sup>1</sup>Department of Parasitology, College of Medicine, Chung-Ang University, Seoul 151

<sup>2</sup>Department of Neurosurgery, College of Medicine, Chung-Ang University, Seoul 140

<sup>3</sup>Department of Neurosurgery, College of Medicine, Seoul National University, Seoul 110

<sup>4</sup>Department of Neurosurgery, St. Mary's Hospital, Catholic Medical College, Seoul 150

<sup>5</sup>Department of Neurology, College of Medicine, Seoul National University, Seoul 110

### INTRODUCTION

Until late 1970s, very few clinical measures could be done for cysticercosis patients. Antiepileptic treatment for seizures, surgery to relieve the increased intracranial pressure either by a shunt operation or by removing the worms blocking the pathway of cerebrospinal fluid (CSF), biopsy of one or more subcutaneous nodules, and prophylactic removal of concomitant *Taenia solium* infection, if any, were those we could do for the patients. As a matter of fact, incidental recovery of *Cysticercus cellulosae* in neurosurgical patients was not uncommon in the endemic areas.

During 1977~1980, however, the developments of computerized tomography (CT) of brain and praziquantel, a chemotherapeutic agent, had changed the management of human cysticercosis. Praziquantel was proved to be effective in both dermal and neurocysticercosis (Rim *et al.*, 1980; Brink *et al.*, 1980; Rim *et al.*, 1982; Botero and Castano, 1982; Spina-Franca *et al.*, 1982; Sotelo *et al.*, 1984). The administration of praziquantel combined with steroid has come to be

recommended as the first choice in neuro-cysticercosis especially in cases of early infection. Praziquantel, however, did not cure all the cysticercosis patients (Rim *et al.*, 1982), and its long term efficacy has yet to be evaluated. Surgical management, therefore, remains still very important in certain situations.

With the progress in medical treatment of cysticercosis, the importance of pre-treatment diagnosis has been grown even more, especially in neuro-cysticercosis. The diagnosis by CT proved to be very useful (Carbajal *et al.*, 1977; Hong *et al.*, 1978; Koh *et al.*, 1980; Rodriguez-Carbajal *et al.*, 1983). CT could visualize the shape, number and location of the intracranial lesions when the cystic worm made a contrast with the inflamed or normal tissue nearby or when calcifications were present. Most neuro-cysticercosis could be diagnosed by CT. Even by CT, however, many cases escaped recognition or gave ambiguous findings to state a definitive aetiological diagnosis. Especially in the cases with a single intracranial lesion of granulomatous nature, aetiological differentiation became difficult. Furthermore, in some ventricular cysticercosis, CT seemed completely normal or showed only a dilated ventricle without visualizing the worm. In such difficult situations, serological tests may provide valuable information for aetiological

\* This study has been supported by a research grant from the Mokam Bioengineering Institute, Inc. (1985).

diagnosis if they are sufficiently sensitive and specific.

Long before the CT era, various serological tests had been studied as a diagnostic tool of systemic- and neuro-cysticercosis (Expert Committee of WHO, 1976; Flisser *et al.*, 1979). Complement fixation (CF) test, indirect haemagglutination test (IHA), gel diffusion (double immunodiffusion, immunoelectrophoresis, counter-immunoelectrophoresis *etc.*), precipitin test, intradermal test, indirect immunofluorescence test, blast transformation *in vitro*, *etc.* were evaluated. As Flisser *et al.* (1979) summarized, these serologic techniques have shown extremely variable results in their sensitivity and specificity. For example, IHA, a widely used method, has been reported by different authors as showing 4~25% of non-specific reactions in serum of normal subjects and 10~92% of sensitivity in confirmed cysticercosis. The relatively high non-specific reaction could be explained by (1) lack of available specific antigen which suppress the cross reactions, (2) difficulty of defining a normal (not infected with *C. cellulosae*) subject especially in endemic area and (3) limited knowledge as to the range of cross-reacting parasitoses.

Flisser *et al.* (1979) also listed possible causes of low sensitivity of the serologic tests in human cysticercosis, as follows; (1) the immunosuppressive effect of anti-inflammatory treatment frequently administered in those patients, (2) different degree of infection, (3) the low sensitivity of the method itself, (4) the existence of different serotypes in the cysticerci population and (5) avoidance of immune recognition. In addition to the above listed factors, the anatomical compartmentalization of antibody production in- and out-side of blood-brain barrier (Leibowitz and Hughes, 1983) might be a reason for the low sensitivity. Neuro-cysticercosis without extracranial infection may reveal a negative reaction when only serum is tested. Also the pathologic status of lesion by the age of infection have affected the results of serologic test (Sotelo *et al.*, 1985).

In order to overcome the compartmentalization

of antibody production in neuro-cysticercosis, if any, the antibody level should also be examined with CSF beside a test of serum only. Already in 1956, Nieto applied CF test to detect anti-*Cysticercus* antibody in CSF; IHA has also been applied to detect the antibody in CSF.

To improve the low sensitivity of the test method itself, the Expert Committee of WHO (1976) recommended the application of the enzyme-linked immunosorbent assay (micro-ELISA) in serological diagnosis of cysticercosis. Since then, many workers have evaluated the applicability of micro-ELISA (Arambulo *et al.*, 1978; Espinoza *et al.*, 1982; Costa *et al.*, 1982; Tellez-Giron *et al.*, 1982; Coker-Vann *et al.*, 1984; Mohammad *et al.*, 1984). Radioimmunoassay was recently applied to detect the specific IgG antibody in serum and CSF (Miller *et al.*, 1984; Mohammad *et al.*, 1984).

Since January 1984 we have also applied the micro-ELISA in detecting the *Cysticercus*-specific IgG antibody in paired samples of serum and CSF in neurologic patients in Korea. In this paper, we report the results of two-year study on the serological diagnosis of neuro-cysticercosis to evaluate the sensitivity, specificity, cross reactivities and related aspects.

## MATERIALS AND METHODS

### 1. Antigens

*Taenia solium* metacestodes (*C. cellulosae*) were collected from two naturally infected hogs slaughtered in Cheju Do, Korea. About 1,000 and 3,000 cysticerci were harvested from each hog, by dissecting the infected muscle. About 40% of worm were removed in unruptured states from the thin fibrous encapsulations without any host tissue debris on its surface. Cystic fluid contaminated on hog muscle was discarded. The unruptured cysts were washed in cold saline for several times. The water on worm surface was removed by rolling on filter paper. Then the cystic fluid from the bladder of worms was pooled in a beaker, bathed at 4°C by gently beating each cyst on a funnel wall. A total of 100ml

of cystic fluid was collected from about 1,300 cysts. The fluid was allocated in freezing vials to keep it at  $-40^{\circ}\text{C}$  until use. The protein content of cystic fluid was 5.0 mg/ml when measured by the method of Lowry *et al.* (1951). The cystic fluid was filtered through 0.45 $\mu\text{m}$  millipore filter membrane to remove particles before use as antigen.

Saline extracts of *Paragonimus westermani* and *Sparganum mansoni* were prepared as Cho *et al.* (1981) and Kim *et al.* (1984) did to observe the cross reactivity in cysticercosis patients. Saline extracts of *Taenia saginata*, *Clonorchis sinensis* and *Fasciola* sp. were also prepared using adult worms.

## 2. Subjects

(1) Subjects in the preliminary observation:

A total of 70 samples of sera was collected at random from freshmen of Chung-Ang University, as normal control. Meanwhile sera from 13 cases of clinically diagnosed neurocysticercosis were secured by the help of Sister Enda M. Stounton, M.D., Dr. H.Y. Shin and Dr. J.J. Suh of St. Isidore Clinic in Cheju Do in 1981. These were epileptic patients with multiple subcutaneous nodules. No cases were examined by

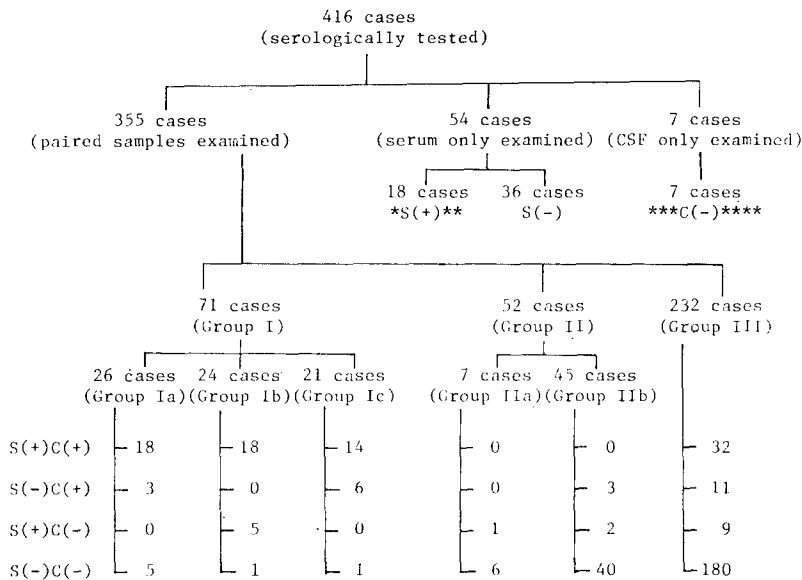
brain CT. Biopsy of skin nodule was done in 2 of 13 cases, which confirmed cysticercosis.

(2) Cases with cysticercosis:

From January 1984 to January 1986 we examined serologically a total of 416 cases for their *Cysticercus*-specific IgG antibody in serum and/or CSF (Fig. 1). Most of the cases were neurologic patients with epileptic seizure, headache or other neurologic symptoms. Most cases were examined by brain CT which revealed normal or abnormal findings. They were in- or out-patients of major university hospitals in Seoul and other cities in Korea.

Out of the 416, 61 cases were excluded from statistics because they were examined only by serum (54 cases) or only CSF (7 cases). The other 355 cases who had been examined by both serum and CSF were subjected to the statistics. All the CSF except in 2 cases were obtained by lumbar puncture. These 2 cases were examined only by ventricular CSF. Three cases were examined by their ventricular CSF in addition to lumbar puncture.

These cases with both samples were divided into 3 groups according to the following criteria (Fig. 1).



\*S: Serum, \*\*(+): Positive, \*\*\*C: CSF, \*\*\*\*(-): Negative

Fig. 1. General scheme of grouping in the present study.

Group I was composed of 71 confirmed cysticercosis. They were selected for a calculation of the sensitivity of micro-ELISA. They were divided into 3 subgroups. *Group Ia* carried 26 cases of surgically proven neuro-cysticercosis. In 3 cases of them, micro-ELISA was done after surgery. Three of them were racemose cysticercosis patients. *Group Ib* was composed of 24 cases of proven cysticercosis by both biopsy of subcutaneous nodules and brain CT findings. All the cases showed multiple low densities in the brain CT. *Group Ic* included 21 cases whose brain CT showed multiple low densities as reviewed by a neuroradiologist.

Group II consisted of 52 cases who had been proven as to be those of other neurologic diseases. They were selected for the calculation of the test specificity. Of them, 7 cases were confirmed by operation as other neurologic diseases such as brain tumor, vascular diseases, head trauma, non-specific granuloma, *etc.* (*Group IIa*). The remaining 45 cases were diagnosed as tuberculous meningitis, fungal infection, vascular diseases, congenital anomaly, *etc.* based on other bacteriological, radiologic data (*Group IIb*). No patient with epilepsy of unknown aetiology was included in Group IIb.

In Groups I and II the result of micro-ELISA for *Cysticercus*-specific IgG antibody did not affected the clinical diagnosis of the patients. Only mutually exclusive cases were included.

Group III consisted of the remaining 232 patients. All cases of neurocysticercosis, whose clinical diagnosis depended on the serological test were included in this group. Those cases with multiple low densities in brain CT were included in Group III when the CT was not reviewed by the neuroradiologist who read the CT of Groups Ib and Ic. Of these, 19 cases were clinically confirmed later as cysticercosis by follow-up brain CT after praziquantel treatment. Other 4 cases were biopsy-confirmed muscular cysticercosis. The clinical diagnosis of the remaining 209 cases was modified by the results of serologic test either as neuro-cysticercosis or as other neurologic diseases. They were, therefore,

excluded from calculation of the sensitivity and specificity.

### (3) Other parasitic infections:

Sera from 110 cases of human parasitic infection were tested to observe the cross reactivity to *Cysticercus* antigen. They were 18 cases of *Taenia saginata* infection, 20 sparganosis, 56 paragonimiasis, 15 clonorchiasis and 1 fascioliasis. Of these, 19 cases were examined of their CSF together with serum because they were manifested by symptoms of central nervous system (CNS).

All of the 18 cases of *T. saginata* infection were confirmed by the worm in stool after praziquantel treatment. Out of 20 cases of sparganosis 4 were confirmed by surgery of subcutaneous nodule, and 2 by neurosurgery. Ten cases were manifested by CNS symptoms; their CSF were also examined. Of the 56 cases of paragonimiasis, 47 were manifested only by pulmonary symptoms; 5 were egg positive by sputum examination and 42 were serologically positive cases. Of the 9 CNS paragonimiasis 4 were surgically confirmed cases and 5 were serologically diagnosed. Fifteen cases of clonorchiasis and one fascioliasis case were all egg confirmed cases.

### 3. Procedures of micro-ELISA

Procedures described by McLaren *et al.* (1978) were followed. Chequerboard titrations were done using Costar polystyrene EIA plate. Two hundred  $\mu$ l of cystic fluid antigen diluted in carbonate buffer (pH 9.6) (in protein concentration of 2.5  $\mu$ g/ml) were coated in wells overnight at 4°C. After washing the wells with saline containing 0.05% Tween 20 for 3 times, 200 $\mu$ l of 1:100 diluted sera in PBS/Tween 20 (pH 7.4) and undiluted CSF in respect were incubated for 2 hours at 37°C. After washing, 200 $\mu$ l of 1:5,000 diluted peroxidase-conjugated antihuman IgG goat serum (H&L chain specific, Cappel, USA) in PBS/Tween 20 (pH 7.4) were incubated for 2 hours at 37°C. After final washing 200 $\mu$ l of substrate, made of 1 ml of 1% o-phenylene diamine, 50 $\mu$ l of 6% H<sub>2</sub>O<sub>2</sub> and 99ml of distilled water were added. The reaction was stopped by adding 20 $\mu$ l of 8N H<sub>2</sub>SO<sub>4</sub> after 30

minutes incubation at 25°C. The absorbance (abs.) was read at 492nm with Gilford spectrophotometer.

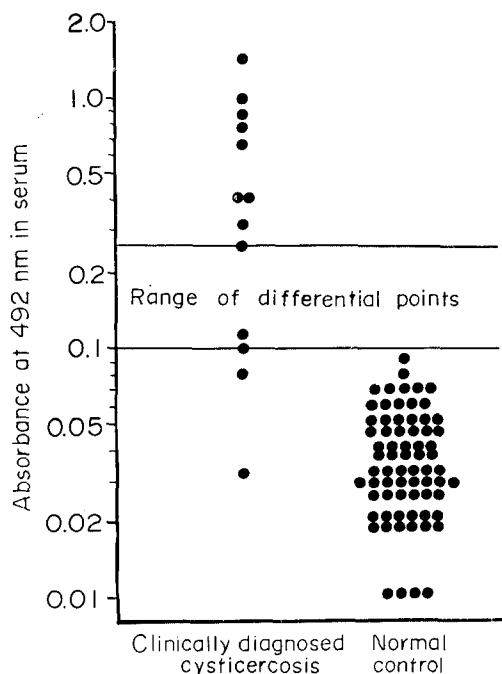
In each test, positive and negative reference sera were concomitantly assayed. The positive reference was chosen which gave the abs. of 1.0 by repeated tests. The abs. of sample sera and CSF was corrected in each assay according to the following formula:

$$\text{Corrected abs. in test sample} = \frac{\text{Reading of abs. in sample}}{\text{Abs. of positive reference}} \times 1$$

## RESULTS

### 1. Preliminary observation

The levels of *Cysticercus*-specific IgG antibody as revealed by the abs. were shown in Fig. 2. In 13 cases of clinically diagnosed cases of neurocysticercosis (epileptic patients with multiple subcutaneous nodules in Cheju Do), the abs. ranged



**Fig. 2.** Results of preliminary observation for *Cysticercus*-specific IgG antibody level in serum of 13 clinically diagnosed neurocysticercosis and 70 cases of normal controls.

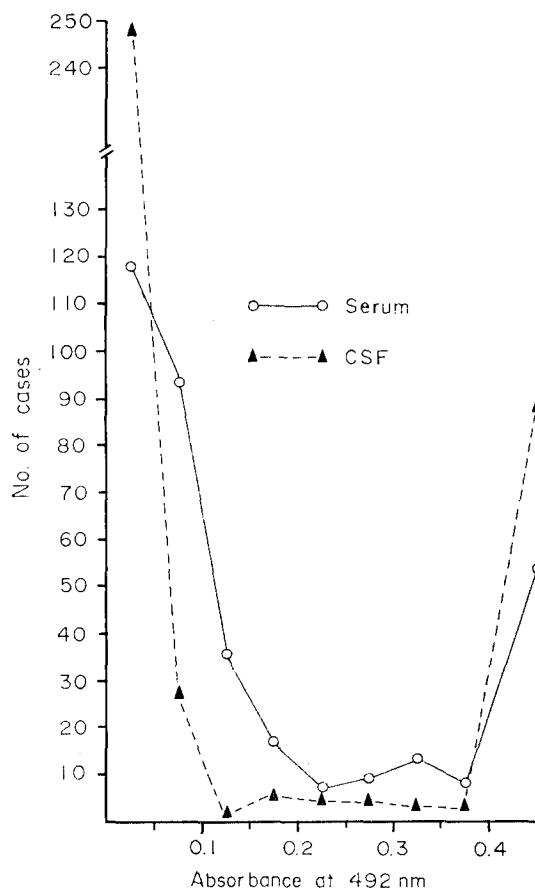
from 0.03 to 1.45. Of the 13, 4 cases showed abs. of lower than 0.11.

The results in 70 normal control cases showed abs. in 0.01~0.09 (mean±standard deviation, 0.04±0.02).

### 2. Criterion of positive reaction

If we had set the criterion at the abs. of upper limit of mean + 2 standard deviation in normal control cases, it would have been 0.08 in this study. From the preliminary observation, however, we thought the differential criterion could be drawn at any abs. between 0.10~0.25 (Fig. 2); the highest abs. in normal control was 0.09 and the lowest abs. in clinically diagnosed cases was 0.25 except for 4 cases who showed far lower abs.

To make the problem of criterion of positive



**Fig. 3.** Frequency distribution of 355 cases by the abs.(level of *Cysticercus*-specific IgG antibody) interval in serum and CSF.

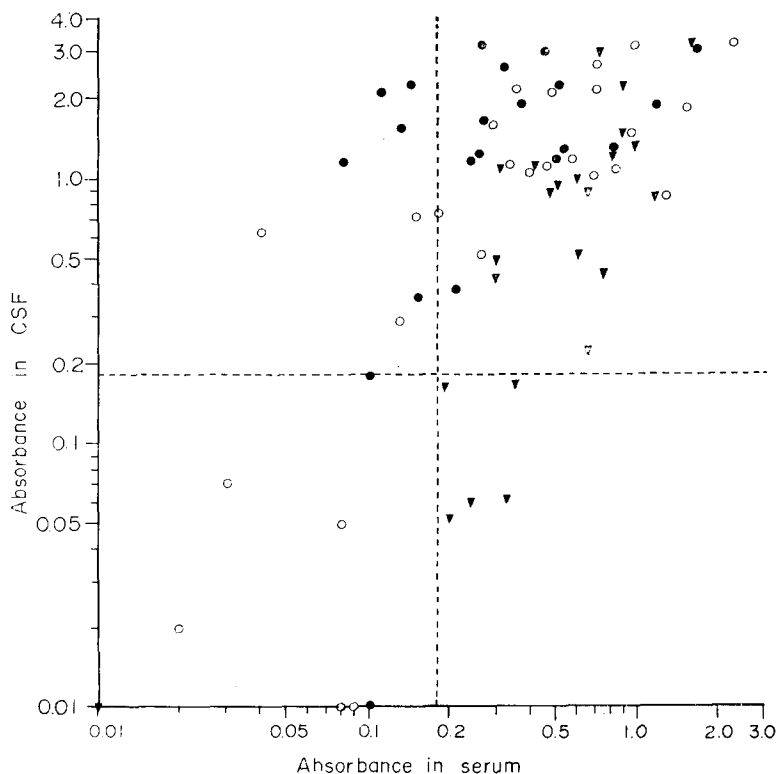
reaction clearer, we analysed the abs. of 355 cases. The number of cases was plotted against the abs. interval 0.05. The frequency of cases was the lowest in 0.21~0.25 when the sera were tested while the lowest frequency was in 0.11~0.15 in CSF (Fig. 3).

Another point we considered was the relation between the positive criterion and the rates of sensitivity and specificity. The higher the abs. of differential criterion, the lower the sensitivity, the higher the specificity and *vice versa*. We thought that, in cysticercosis, the specificity should have a priority over the sensitivity because the present assay should differentiate as much cysticercosis as possible from other neurologic diseases as aetiologic diagnosis.

The last point we considered was whether or

not the same differential abs. should be applied to 1:100 diluted serum and undiluted CSF. In normal cases, the protein content in CSF is 1/200~1/400 of serum; and the concentration of total immunoglobulin is 1/500 of serum (Leibowitz and Hughes, 1983). As observed by McCormick *et al.* (1982), however, immunoglobulin levels in CSF in neurocysticercosis patients became 1/100 of serum. We thought, therefore, that the same abs. could be applied as a differential criterion in both serum and CSF in our assay condition.

From the considerations, we set arbitrarily the abs. of 0.18 as the lowest limit of positive reaction. It was a mid-point between the possible ranges of criterion in the preliminary observation (Fig. 2) and also a mid-point of the abs. ranges of the lowest frequency in sera



**Fig. 4.** Distribution of the abs. (specific IgG antibody level) in serum and CSF in confirmed neurocysticercosis patients (Group I). Open circle (○) : Neurosurgery confirmed (Group Ia). Closed triangle (▼) : Subcutaneous nodule biopsy and brain CT positive (Group Ib). Closed circle (●) : Multiple low densities in brain CT (Group Ic). Transverse and vertical dotted lines at the abs. of 0.18 are positive criteria.

**Table 1.** The sensitivity of micro-ELISA in neuro-cysticercosis

Group	No. evaluated	No. of cases of			
		serum(+) CSF (+)	serum(-) CSF (+)	serum(+) CSF (-)	serum(-) CSF (-)
I a	26	18	3	0	5
I b	24	18	0	5	1
I c	21	14	6	0	1
Total	71	50	9	5	7

Sensitivity of micro-ELISA by serum: 77.5%

Sensitivity of micro-ELISA by CSF : 83.1%

Overall sensitivity : 90.1%

(0.21~0.25) and in CSF(0.11~0.15) (Fig. 3).

### 3. Sensitivity of assay

As shown in Table 1, a total of 71 cases of Group I was subjected to a calculation of the sensitivity. Of them, abs. was above the positive criterion in 64 cases(90.1%) when any of serum or CSF showed positive. When the results in serum only were considered the sensitivity of assay was 77.5%(55/71) and that in CSF only was 83.1%(59/71). Seven cases out of 71 showed negative reaction in both samples.

The sensitivity of micro-ELISA was lower in Group Ia than in Groups Ib or Ic. In Group Ia, 3 cases were tested on 2~20 days after neurological surgery. One of them had a single intracranial lesion, whose result was negative both in serum and CSF. Three additional cases with a single intracranial lesion, who were tested before surgery, were negative in both samples.

As shown in Fig. 4, most of the serologically negative cases of confirmed neurocysticercosis showed the lowest abs. either in serum or in CSF; the intermediate ranges were rare in such

false negative cases.

### 4. Specificity of assay

As shown in Table 2, a total of 52 cases of Group II was subjected to a calculation of the specificity. Of them 46 cases(88.5%) showed the negative results both in serum and in CSF. When the results by serum were considered the specificity was 94.2% (49/52) and when those of CSF only were considered, it was 94.2% (49/52). No case was positive in both serum and CSF.

In surgically confirmed other neurologic diseases (Group IIa), the specific results were obtained in 6 of 7 cases(87.5%) while in medically diagnosed cases(Group IIb), specificity was 88.9% (40/45). As shown in Fig. 5, the non-specific positive reactions in Group II revealed their abs. near to the positive criterion. Only exception was a child with tuberculous meningitis who showed a high abs. in CSF.

### 5. Results in remaining cases

The overall positive rates of 355 subjected cases are shown in Fig. 1. Out of them 82 cases

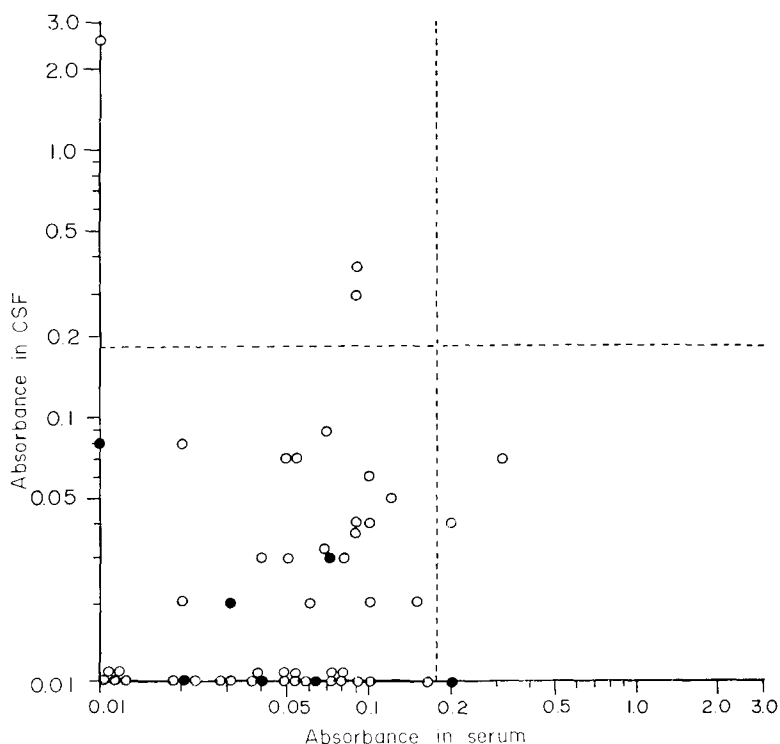
**Table 2.** The specificity of micro-ELISA in neuro-cysticercosis

Group	No. evaluated	No. of cases of			
		serum(+) CSF (+)	serum(-) CSF (+)	serum(+) CSF (-)	serum(-) CSF (-)
II a	7	0	0	1	6
II b	45	0	3	2	40
Total	52	0	3	3	46

Specificity of micro-ELISA by serum: 94.2%

Specificity of micro-ELISA by CSF : 94.2%

Overall specificity : 88.5%



**Fig. 5.** Distribution of the abs. (specific IgG antibody level) in serum and CSF in confirmed other neurologic diseases (Group II). Closed circle(●) : Surgically diagnosed other neurologic diseases (Group II a). Open circle(○) : Medically diagnosed other neurologic diseases(Group II b). Dotted lines at abs. of 0.18 are the differential criteria of the positive reaction.

(23.1%) were positive in both samples, 17 cases (4.8%) were positive only in serum, 23 cases (6.5%) were positive only in CSF and 233 cases(65.9%) were negative in both samples, if the correctness of the results of micro-ELISA was disregarded.

In Fig. 6, the abs. in serum and CSF of 232 cases of Group III are shown. The pattern of abs. distribution was basically identical with those of Figs. 4 & 5 combined. Of the 232, 4 cases were biopsy confirmed muscular cysticercosis, with normal brain CT findings. Their abs. were shown with a separate marking. In 19 cases who were diagnosed by follow-up CT after the empirical praziquantel treatment, the sensitivities were 57.9% by serum and 73.7% by CSF. The overall sensitivity in these was 78.9%.

### 6. Cross reactivity

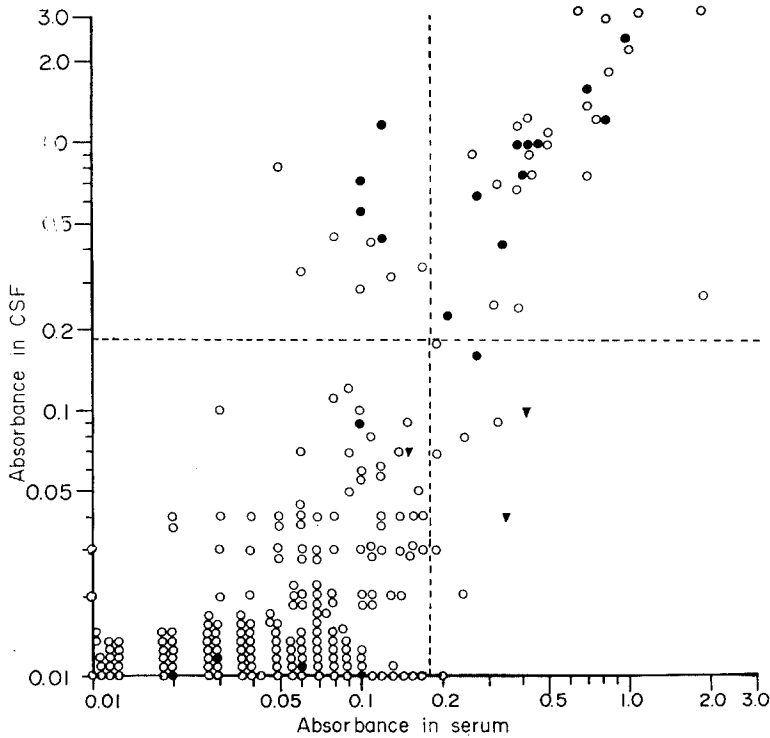
As shown in Table 3, a total of 110 cases of trematode and cestode infections were examined

for *Cysticercus*-specific IgG antibody levels as well as for homologous IgG antibody. In 7 cases of them, abs. was higher than the positive criteria. Any parasitic infection tested may show cross reactions though the incidence was low. The abs. for *Cysticercus*-specific IgG antibody was always lower than those to homologous antigens except in 2 cases(Fig. 7).

In 19 cases who were examined by their CSF, the cross reaction was observed in 2 neurosparganosis while no cerebral paragonimiasis case showed any cross reaction.

To check the cross reactivity of neuro-cysticercosis patients to other antigens, 71 cases in Group I were tested for their *Paragonimus*- and *Sparganum*-specific IgG antibody levels in serum and CSF. Table 4 shows the result indicating that neuro-cysticercosis patients revealed no cross reactivity to *Paragonimus* antigen either in serum or in CSF. To *Sparganum* antigen, how-





**Fig. 6.** Distribution of the abs. in serum and CSF in the remaining cases (Group III). Closed circle(●) : Clinically diagnosed as neurocysticercosis by follow-up CT after praziquantel treatment. Closed triangle(▼) : Biopsy confirmed muscular cysticercosis without neurologic symptoms or with normal brain CT. Open circle(○) : Not confirmed cases of neuro-cysticercosis or other neurologic diseases. Dotted lines are differential criteria of the positive reaction.

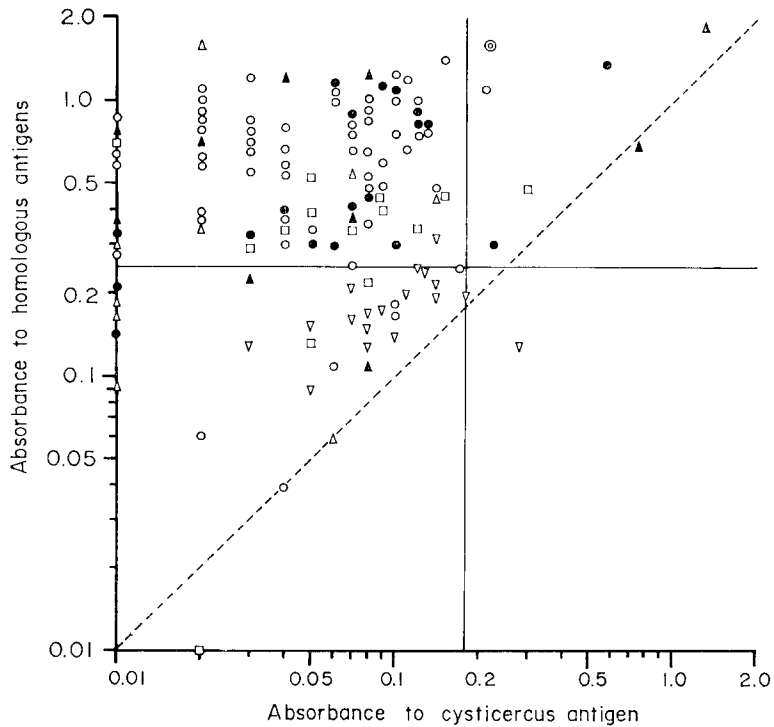
**Table 3.** Incidence of cross reactions in sera and CSF of other parasitic infections to *Cysticercus* antigen

Infected parasite	No. of sera		No. of CSF	
	examined	positive	examined	positive
<i>Taenia saginata</i>	18	2	0	—
Sparganum	20	2	10	2
<i>Paragonimus westermani</i>	56	1	9	0
<i>Clonorchis sinensis</i>	15	1	0	—
<i>Fasciola</i> sp.	1	1	0	—

ever, 6 cases(8.5%) out of 71 revealed positive reaction when serum was tested, and 11 cases (15.5%) were positive when CSF was tested. All the cross reacted cases to sparganum antigen revealed a high antibody level either in serum or in CSF. No case showed positive reactions in both samples. The abs. to sparganum antigen was always lower than that to *Cysticercus* antigen.

**Table 4.** Incidence of cross-reaction in 71 cases of neuro-cysticercosis(Group I) to *Paragonimus* and sparganum antigens

Antigen	No. of cross-reacted cases in	
	serum	CSF
<i>Paragonimus westermani</i>	0	0
Sparganum	6	11



**Fig. 7.** Relations of the abs. in serum and CSF in other parasitic infections to *Cysticercus* and homologous antigens. Transverse line at abs. of 0.25 is the positive criterion of other parasitic infections. Vertical line at abs. of 0.18 is criterion for cysticercosis. Dotted oblique line is  $y=x$ . Open circle( $\circ$ ) : Abs. in serum of paragonimiasis cases. Open triangle( $\Delta$ ) : Abs. in CSF of paragonimiasis cases. Closed circle( $\bullet$ ) : Abs. in serum of sparganosis cases. Closed triangle( $\blacktriangle$ ) : Abs. in CSF of sparganosis cases. Open rectangle( $\square$ ) : Abs. in serum of clonorchiasis cases. Inverted open triangle( $\nabla$ ) : Abs. in serum of taeniasis cases. Double circle( $\odot$ ) : Abs. in a serum of fascioliasis.

### 7. Relation of the specific antibody levels between serum and CSF

As shown in Fig. 3, the abs. in CSF distributed more frequently in lower and higher ranges than the abs. in sera did. The frequency in the intermediate range of abs. (0.1-0.4) was lower in CSF than in sera. This difference of distribution pattern was statistically significant ( $\chi^2=122.84$ ,  $p<0.01$ ). We did not think that this difference was a result of technical discrepancy of test condition, especially the dilution factor between sera (1:100) and CSF (undiluted). As shown in Figs. 4-6, 39 cases out of 355 (11.0%) revealed different results of antibody levels between serum and CSF in terms of positive/negative reaction. The above data suggested that the antibodies in serum and CSF had been

produced independently.

Of 355 cases, two cases presented a history corresponding to the independent production of the specific antibody in serum and CSF.

*Case 1:* HKR, a 59-year old male, with a complaint of right flank pain. The radiological examinations showed multiple calcified lesions in muscles of chest and abdominal wall. He had neither focal neurologic symptoms and signs nor epileptic seizures. Brain CT was not done. The abs. in serum was 0.35(+) for *Cysticercus*-specific IgG antibody, whereas lumbar CSF showed abs. of 0.04(-).

*Case 2:* HJP, a 13-year old male patient had a recent seizure episode just after a head trauma. Two years ago, he had multiple subcutaneous nodules, which were confirmed as *Cysticercus* by

a biopsy. His brain CT at the present admission was normal. The abs. in serum was 0.41(+) while that in lumbar CSF was 0.10(-). Clinically the patient's recent seizure was diagnosed not due to neuro-cysticercosis.

The above two cases indicated that the *Cysticercus*-specific IgG antibody did not cross over blood-CSF barrier in a significant amount even when the level was sufficiently high in serum.

### 8. Specific IgG antibody level in ventricular CSF

During the period of this study, there were 5 occasions of examining the ventricular CSF. Their history could be summarized as follows:

*Case 3:* HY, a 13-year old male with headache, convulsions and multiple subcutaneous nodules. Brain CT revealed the dilatations of lateral ventricles and multiple low densities in brain parenchyme. Ventriculoperitoneal (VP) shunt operation was done after conray ventriculography, which showed multiple masses in lateral ventricle. The abs. in ventricular CSF was 3.35(+) and that in serum was 1.77(+). He was not examined by lumbar CSF.

*Case 4:* BGL, a 47-year old male patient with the complaints of the memory loss and weakness of lower extremities had multiple subcutaneous nodules. Brain CT showed multiple low densities. Conray ventriculography revealed a cystic mass at the right frontal horn. His serum and ventricular CSF were examined. The abs. in serum was 0.82(+) and that in ventricular CSF was 1.11(+). Lumbar puncture was not allowed because of increased intracranial pressure.

*Case 5:* KWN, a 48-year old female patient with dizziness and headache. Brain CT showed dilatation of ventricles with a ring enhancement in Sylvian cistern. Ventricular CSF was examined for the *Cysticercus*-specific IgG antibody level together with her serum. The abs. in serum was 0.42(+) and that in ventricular CSF 0.24(+). Conray ventriculography showed a mass at the 4th ventricle. A week later, lumbar CSF was obtained; the abs. was 1.00(+).

*Case 6:* HYC, an 8-year old female patient, complaining of headache and vomiting was ex-

amined by brain CT. A markedly dilated 4th ventricle was shown. Ventricular CSF revealed the abs. of 0.08(-) while that in serum was 0.38(+). Four days after VP shunt operation, lumbar CSF was examined; It showed the abs. as high as 1.17(+).

*Case 7:* MHK, a 61-year old male patient with headache was examined by brain CT which revealed dilatation of the 4th ventricle. Serum showed the abs. of 0.51(+) and the lumbar CSF showed 1.30(+). Ten days later, ventriculography was done. CSF from the lateral ventricle showed the abs. of 0.15(-).

The above 5 cases indicated that ventricular CSF in obstructive hydrocephalus due to cysticercosis had significantly lower antibody levels than lumbar CSF unless the worm was located at the lateral ventricle itself.

### 9. Findings in racemose cysticercosis:

There were 4 cases of racemose cysticercosis confirmed by neurosurgery in this study. Three of them were included in Group Ia. One case was tested by serum only; therefore excluded from Groups I, II and III. Their results of the specific IgG antibody were shown in Table 5.

**Table 5.** Results of serological tests in 4 racemose cysticercosis for the specific IgG antibody by micro-ELISA

Case	Abs. in		Days after surgery, tested
	serum	CSF	
RC case 1	0.26(+)	0.52(+)	2 days
RC case 2	0.13(-)	0.29(+)	20 days
RC case 3	0.47(+)	2.10(+)	Pre-op.
RC case 4	0.58(+)	not done	2 days

## DISCUSSION

Many authors have evaluated the applicability of micro-ELISA in cysticercosis. Using delipidized saline extracts of *T. solium* and its cysticerci, Arambulo *et al.* (1978) reported firstly that the sensitivity was 77.6% in 49 suspected cysticercosis patients. Some of hydatid disease and schistosomiasis cases showed cross reaction to *Cysticercus* antigen. Costa *et al.* (1982) reported

that all of 22 confirmed cases of neuro-cysticercosis were positive by micro-ELISA for IgG antibody in their CSF. Using purified antigen B of Flisser *et al.* (1980), Espinoza *et al.* (1982) reported the sensitivity of ELISA was 73% by serum and 85% by CSF assays in 13 confirmed neuro-cysticercosis. Tellez-Giron *et al.* (1982) compared ELISA with IHA in diagnosis of cysticercosis. All of 17 sera of confirmed cysticercosis were positive by ELISA while 5 cases were false negative by IHA. Diwan *et al.* (1982) reported that 61% of sera from 31 Irian Jaya patients of cysticercosis was positive by ELISA. Cross reaction occurred in schistosomiasis, echinococcosis and angiostrongyliasis. Using partially purified antigen of *C. cellulosae* by chromatofocusing procedure, Coker-Vann *et al.* (1984) reported the sensitivity of micro-ELISA as 80% in 20 sera of Irian Jaya patients. Mohammad *et al.* (1984) applied ELISA in sera and CSF of 19 confirmed neuro-cysticercosis. ELISA by serum had a sensitivity of 89.5% and a specificity of 100% while the sensitivity and specificity of CSF assay were 94.7% in respect.

In terms of its sensitivity and specificity, the diagnostic ability of micro-ELISA in neuro-cysticercosis using paired samples of serum and CSF was very good in this study. Results were, however, not as excellent as reported by Costa *et al.* (1982), Tellez-Giron *et al.* (1982) and Mohammad *et al.* (1984). Present results were comparable with those by Espinoza *et al.* (1982) and Diwan *et al.* (1982). We thought that somewhat inferior results among various reports were not due to problem of ELISA itself. As reviewed by Draper and Lillywhite (1984), micro-ELISA is one of the most promising techniques in all of its sensitivity, reproducibility, safety, simplicity and price. Therefore, the somewhat inferior finding in this study was considered to be attributable to wider case coverage rather than the problems in the technique.

In this study we applied micro-ELISA in 355 cases of neurologic patients of various manifestations. Of them 71 cases were selected as confirmed neuro-cysticercosis; of 71, 26 cases were

surgically confirmed. Out of 26 surgically confirmed cases 5 showed negative IgG antibody in both samples. Four cases of the 5 had a single intracranial lesion. This suggested that the number of lesion may be related with the antibody level; but there have been yet no definite report which confirmed this relation.

Since the introduction of praziquantel in treatment of cysticercosis, the policy of patient management began to change. Less cases of neuro-cysticercosis are subjected to surgery than in the past. Nowadays those with a single lesion are liable to surgery than multiply involved. In cases of increased intracranial pressure, VP shunt is preferred. All of the above listed factors may affect the sensitivity of micro-ELISA in the present study, to become somewhat inferior.

Though micro-ELISA is sensitive and reproducible, there remained many aspects to be improved especially in application to cysticercosis. The antigen should be improved in its quality. The crude extracts need purification to eliminate cross-reacting components with other parasitic infections (Flisser *et al.*, 1979). In this respect, Grogl *et al.* (1985) analysed *C. cellulosae* extract by enzyme-linked immuno-electrophoretic transfer blot. They identified 37 protein bands which reacted with sera of 5 human neuro-cysticercosis cases. Polypeptides of 64K, 53K, and 32-30K daltons were candidates of the best diagnostic antigens. Rhoads *et al.* (1985) reported a fraction of cystic fluid of *T. hydatigena* metacestode was promising as a diagnostic antigen of bovine cysticercosis. Choi *et al.* (1986) indicated that cystic fluid of *C. cellulosae* was more sensitive and specific antigen than saline extracts of any other anatomical parts of the worm when analysed by micro-ELISA. Disc-polyacrylamide gel electrophoresis of cystic fluid showed 6 protein bands; therefore the best antigenic protein should be identified and isolated from them. In this study cystic fluid was used as antigen instead of crude extract of the parenchymal tissue. Unlike the above study results, Flisser *et al.* (1980) identified by immunoelectrophoresis that antigen B from parenchymal tissue was the most sensitive

antigen. Guerra *et al.* (1982) purified the antigen B and determined its molecular weight as 105K and 95K daltons. It is not known at this moment, however, among diverse antigenic proteins which is the most frequently reacting one with equally diverse polyclonal antibodies.

Another aspect that needs improvement is developing a method of detecting antigenemia or antigen in CSF. Diagnosis of cysticercosis may be supplemented by this. As shown in Figs. 4 and 6, many false negative cases showed far lower level of IgG antibody rather than marginal levels. We conjectured that most of them were either in early (Nieto, 1956) or in late inactive stages of infection. Sotelo *et al.* (1985) differentiated active cysticercosis from inactive forms based on clinical manifestations and laboratory data. In inactive cases the sensitivity of CF test decreased to 23.2% while it was positive in 83.4% of active cases with inflammatory CSF. Detection of antigenemia, therefore, may be helpful especially in diagnosis of the early cysticercosis.

The value of CSF in detecting the specific antibody has long been known in cysticercosis (Nieto, 1956). Many neuro-cysticercosis cases developed their symptoms without subcutaneous nodules. Reversely, cases with nodules can not be definitely stated to have intracranial lesion. Examination of antibody in CSF seemed, therefore, to be very helpful to make a correct diagnosis of neuro-cysticercosis. Actually 9 out of 71 confirmed cases in this study showed antibody only in CSF whereas 5 were positive only in serum.

So far, this study was the first in observing quantitative relations of *Cysticercus*-specific antibody levels between serum and CSF. It is too early to make any conclusion, but our data suggested strongly that the majority of the specific IgG antibody in CSF was produced in the intracranial lesion rather than they are contributed by filtration through blood-CSF barrier or by exudation through damaged blood-brain barrier at brain lesion (Leibowitz and Hughes, 1983). Actually muscular cysticercosis

without intracranial lesion showed negative antibody level in CSF though positive in serum. In addition, 5 cases in Group Ib whose brain CT showed typical lesions of neuro-cysticercosis were negative in CSF antibody while positive in serum. These results have been obtained by comparable dilutions of serum and CSF for measurement of the specific IgG antibody in CSF. Many quantitative aspects of the antibody levels between serum and CSF needs further researches in neuro-cysticercosis.

CSF from lateral ventricle have been available during ventriculography or VP shunt operation which are done most frequently in obstructions at the 4th ventricle (Zee *et al.*, 1984). These ventricular CSF showed negative or low level of antibody unless the worm located at the lateral ventricle. Nieto (1956) also described 10 such cases who showed different antibody levels between ventricular and lumbar CSF. This difference may be due to lower protein concentration in ventricular CSF than in lumbar CSF (Nieto, 1956; Leibowitz and Huhges, 1983). The mechanism of the difference, however, may not be simple as the above. Whatever the mechanism of the difference was, the level of the specific IgG antibody in ventricular CSF should be interpreted with caution in intracranial hypertension cases in whom the ventricular CSF is frequently the only material for assay. In this respect, Salazar *et al.* (1983) reported that all of 8 ventriculitis cases showed positive antibody level in lumbar CSF while only 2 out of 8 cases of the fourth ventricular cyst were positive in lumbar CSF; and even in ventriculitis cases, ventricular CSF were negative for antibody. Sotelo *et al.* (1985) interpreted these findings as an indication of the local production of antibody in the subarachnoid space. Our data were in agreement with them.

If the antibody in serum and CSF are produced by extra- and intracranial infections in respect, the positive cases in serum would indicate that there are concomitant systemic infection whether apparent or hidden. The cases with antibody only in CSF would indicated the intra-

cranial infection without extracranial involvement. Real situation would not be simple as the above; data of clinical cases should be evaluated in this respect.

Biagi *et al.* (1961) observed in racemose cysticercosis cases the higher frequency of positive precipitin reaction with antigen from racemose cysticercus than from normal *C. cellulosae*. They speculated that this may be due to different antigenic compositions between them. That was one of the reasons for speculating antigenic variation among *C. cellulosae* population (Yakoleff-Greenhouse *et al.*, 1982). So far our cases of racemose cysticercosis showed no difference of antibody level from conventional cases.

### SUMMARY

The applicability of micro-ELISA was evaluated in human neuro-cysticercosis using paired samples of serum and CSF. A total of 355 cases who were mostly neurologic patients was subjected. Cystic fluid of *C. cellulosae* was used as antigen in protein concentration of 2.5 µg/ml. Serum was diluted to 1:100 and CSF was undiluted in the assay for the specific IgG antibody level. The differential criterion of the positive reaction was the abs. of 0.18 in both samples. The results were summarized as follows:

1. The overall sensitivity of the micro-ELISA in 71 confirmed neurocysticercosis was 90.1%; the sensitivity by serum was 77.5% and that by CSF was 83.1%. CSF was a more sensitive and valuable material. Most of the false negative cases of neuro-cysticercosis showed far lower level of abs. rather than marginal.

2. The overall specificity of the micro-ELISA in 52 confirmed other neurologic diseases was 88.5%; the specificities by serum and by CSF were 94.2% respectively. Cases of other neurologic diseases did not show false positive reactions in both samples.

3. When serum was assayed, taeniasis(2/18), sparganosis(2/20), paragonimiasis(1/56), clonorchiasis(1/15) and fascioliasis(1/1) cases showed

cross reactions. When CSF was assayed, 2 of 10 neuro-sparganosis showed cross reactions while none of 9 neuro-paragonimiasis showed it. Out of 71 confirmed neuro-cysticercosis cases, 6 and 11 showed cross reactions by serum and CSF to crude extract antigen of sparganum; but no case did show it to crude extract antigen of *Paragonimus westermani*.

4. Ventricular CSF showed low or negative levels of IgG antibody than lumbar CSF unless the lesion was at the lateral ventricle itself.

5. Out of 4 racemose cysticercosis cases, 3 showed positive reaction in serum while all of 3 examined CSF were positive.

The above results indicated that the serological test for detecting the specific IgG antibody by micro-ELISA using paired samples of serum and CSF was very helpful for clinical differentiation of neuro-cysticercosis from neurologic diseases of other causes.

### ACKNOWLEDGEMENTS

We express thanks to Dr. Young Bae Kang and Dr. Young Jeon of the Institute of Veterinary Research, Rural Development Administration in Anyang City, and to Dr. H.K. Moon of Hallim Abattoir for help in obtaining pigs infected with *C. cellulosae*. We also express thanks to Sister Enda M. Stounton, M.D., Dr. Hee Young Shin, Dr. Jong Jin Suh of St. Isidore Clinic for provision of the valuable sera of clinically diagnosed neuro-cysticercosis. Assist. Professor K.H. Chang, Department of Diagnostic Radiology, Seoul National University Hospital provided us the brain CT findings of cases of Group Ib and Ic in this study. Professor Y.K. Ahn, Wonju Medical School, Yonsei University provided us a serum of human fascioliasis case. We are indebted to many neurologists, neurosurgeons and pathologists for their gladly and kind cooperations in obtaining case history and final diagnosis of the serologically tested patients.

## REFERENCES

- Arambulo, P.V., Walls, K., Bullock, S. and Kagan, I.G. (1978) Serodiagnosis of human cysticercosis by microplate enzyme-linked immunospecific assay (ELISA). *Acta tropica*, 15:63-67.
- Biagi, F., Briceno, C.E. and Martinez, B. (1961) Diferencias entre *Cysticercus cellulosae* y *C. racemosus*. *Rev. biol. trop.*, 9:141-151.
- Botero, D. and Castano, S. (1982) Treatment of cysticercosis with praziquantel in Colombia. *Am. J. Trop. Med. Hyg.*, 31(4):810-821.
- Brink, G., Schenone, H., Diaz, V., Parra, M. and Corrales, M. (1980) Neurocysticercosis: Treatment with praziquantel; a preliminary study. *Bol. Chil. Parasitol.*, 35:66-71.
- Carbajal, J.R., Palacios, E., Azar-Kia, B. and Churchill, R. (1977) Radiology of cysticercosis of the central nervous system including computed tomography. *Radiology*, 125:127-131.
- Cho, S.Y., Hong, S.T., Rho, Y.H., Choi, S. and Han, Y.C. (1981) Application of micro-ELISA in serodiagnosis of human paragonimiasis. *Korean J. Parasit.*, 19(2):151-156.
- Choi, B.K., Kim, S.I., Kang, S.Y. and Cho, S.Y. (1986) Evaluation of antigens from different parts of *Cysticercus cellulosae* in serological diagnosis of human cysticercosis. *Chung-Ang J. Med.*, 11(2):135-146.
- Coker-Vann, M., Brown, P. and Gajdusek, D.C. (1984) Serodiagnosis of human cysticercosis using a chromatofocused antigenic preparation of *Taenia solium* cysticerci in an enzyme-linked immunosorbent assay. *Trans. Roy Soc. Trop. Med. Hyg.*, 78:492-496.
- Costa, J.M., Ferreira, A.W., Makino, M.M. and Camargo, M.E. (1982) Spinal fluid immunoenzymatic assay (ELISA) for neurocysticercosis. *Rev. Inst. Med. Trop. Sao Paulo*, 24(6):337-341.
- Diwan, A.R., Coker-Vann, M., Brown, P., Subianto, D.B., Yolken, R., Desowitz, R., Escobar, A., Gibbs, C.J. and Gajdusek, D.C. (1982) Enzyme-linked immunosorbent assay (ELISA) for the detection of antibody to cysticerci of *Taenia solium*. *Am. J. Trop. Med. Hyg.*, 31(2):364-369.
- Draper, C.C. and Lillywhite, J.E. (1984) Immunodiagnosis of tropical parasitic infections. In: Gilles, H.M. (ed.): *Recent advances in tropical medicine*, Vol. 1:267-288, Churchill Livingstone, Edinburgh.
- Espinoza, B., Flisser, A., Plankarte, A. and Larralde, C. (1982) Immunodiagnosis of human cysticercosis: ELISA and immunoelectrophoresis. In: Flisser, A. et al. (eds.): *Cysticercosis: Present status of knowledge and perspectives*, 163-170, Academic Press, New York.
- Expert Committee, WHO (1976) Research needs in taeniasis-cysticercosis (memorandum). *Bull. Wld. Hlth. Org.*, 53:67-73.
- Flisser, A., Perez-Mountfort, R. and Larralde, C. (1979) The immunology of human and animal cysticercosis; a review. *Bull. Wld. Hlth. Org.*, 57(5):839-856.
- Flisser, A., Woodhouse, E. and Larralde, C. (1980) Human cysticercosis: antigens, antibodies and non-responders. *Clin. exp. Immunol.*, 39:27-37.
- Grogl, M., Estrada, J.J., McDonald, G.M. and Kuhn, R.E. (1985) Antigen-antibody analyses in neurocysticercosis. *J. Parasit.*, 71(4):433-442.
- Guerra, G., Flisser, A., Canedo, L. and Lacleite, J. P. (1982) Biochemical and immunological characterization of antigen B purified from cysticerci of *Taenia solium*. In: Flisser, A. et al. (eds.): *Cysticercosis: Present status of knowledge and perspectives*, 437-451, Academic Press, New York.
- Hong, S.K., Choi, K.S. and Sim, B.S. (1978) Cysticercosis of the central nervous system. *J. Korean Neurosurg. Soc.*, 7(2):417-423.
- Kim, H., Kim, S.I. and Cho, S.Y. (1984) Serological diagnosis of human sparganosis by means of micro-ELISA. *Korean J. Parasit.*, 22(2):222-228.
- Koh, Y.C. and Sim, B.S. (1980) CT findings of parasitic infestations of the brain in Korea. *J. Korean Neurosurg. Soc.*, 9(1):7-18.
- Leibowitz, S. and Hughes, R.A.C. (1983) Immunology of the nervous system. Edward Arnold, London.
- Lowry, O.H., Rosenbrough, N.J., Lewis-Farr, A. and Randall, R.J. (1951) Protein measurement with Folin phenol reagent. *J. Biol. Chem.*, 193:265-275.
- McCormick, G.F., Zee, C-S. and Heiden, J. (1982) Cysticercosis cerebri: Review of 127 cases. *Arch. Neurol.*, 39:534-539.
- McLaren, M., Draper, C.C., Roberts, J.M., Minter-Goedbloed, E., Lighthart, G.S., Teesdale, C.H., Amin, M.A., Omer, A.H.S., Bartlett, A. and Voller, A. (1978) Studies on the enzyme-linked immunosorbent assay (ELISA) test for *Schistosoma mansoni* infections. *Ann. Trop. Med. Parasit.*, 72(3):243-253.
- Miller, B., Goldberg, M.A., Heiner, D., Myers, A. and Goldberg, A. (1984) A new immunologic test

- for CNS cysticercosis. *Neurology*, **34**:695-697.
- Mohammad, I.N., Heiner, D.C., Miller, B.L., Goldberg, M.A. and Kagan, I.G.(1984) Enzyme-linked immunosorbent assay for the diagnosis of cerebral cysticercosis. *J. clin. Microbiol.*, **20**(4):775-779.
- Nieto, D.(1956) Cysticercosis of the nervous system. Diagnosis by means of the spinal fluid complement fixation test. *Neurology*, **6**:725-738.
- Rhoads, M.L., Murrell, K.D., Dilling, G.W., Wong, M.M. and Baker, N.F.(1985) A potential diagnostic reagent for bovine cysticercosis. *J. Parasit.*, **71**(6):779-787.
- Rim, H.J., Won, C.R. and Chu, C.W.(1980) Studies on the cysticercosis and its therapeutic trial with praziquantel(Embay 8440). *Korea Univ. Med. J.*, **17**(3):459-476.
- Rim, H.J., Lee, J.S., Joo, K.H., Kim, S.J., Won, C.R. and Park, C.Y.(1982) Therapeutic trial of praziquantel(Embay 8440; Biltricide) on the dermal and cerebral human cysticercosis. *Korean J. Parasit.*, **20**(2):169-190.
- Rodriguez-Carbajal, J., Salgado, P., Gutierrez, R., Escobar, A., Aruffo, C. and Palacios, E.(1983) The acute encephalitic phase of neurocysticercosis; computed tomographic manifestations. *Am. J. Neuro-radiol.*, **4**:51-55.
- Salazar, A., Sotelo, J., Martinez, H. and Escobedo, F.(1983) Differential diagnosis between ventriculitis and fourth ventricular cyst in neurocysticercosis. *J. Neurosurg.*, **59**:660-663.
- Sotelo, J., Escobedo, F., Rodriguez-Carbajal, J., Torres, B. and Rubio-Donnadieu, F.(1984) Therapy of parenchymal brain cysticercosis with praziquantel. *New Engl. J. Med.*, **310**:1001-1007.
- Sotelo, J., Gurrero, V. and Bubio, F.(1985) Neurocysticercosis. A new classification based on active and inactive forms. *Arch. Int. Med.*, **145**:442-445.
- Tellez-Giron, E., Ramos, M.C., Dufour, L. and Montante, M.(1982) Aplicacion del metodo ELISA para el diagnostico de la cisticercosis. *Boletin de Oficina Sanitaria Panamericana*, **96**(6):8-13. (cited from *Helminthological Abstracts*).
- Yakoleff-Greenhouse, V., Flisser, A., Sierra, A. and Larralde, C.(1982) Analysis of antigenic variation in cysticercosis of *Taenia solium*. *J. Parasit.*, **68** (1):39-47.
- Zee, C-S., Segall, H.D., Apuzzo, M.L.J., Ahmadi, J. and Dobkin, W.R.(1984) Intraventricular cysticercal cysts: Further neurologic observations and neurosurgical implications. *Am. J. Neuroradiol.*, **5**:727-730.



==국문초록==

면역효소측정법을 이용한 뇌낭미충증의 혈청학적 진단의 평가

중앙대학교 의과대학 기생충학교실 및 신경외과학교실\*

조승열 · 김석일 · 강신영 · 최덕영\* · 석중식\*

서울대학교 의과대학 신경외과학교실

최 길 수

가톨릭의대 신경외과학교실

하 영 수

서울대학교 의과대학 신경과학교실

정 진 상 · 명 호 진

뇌낭미충증환자 혈청 및 뇌척수액의 특이 IgG 항체를 면역효소측정법으로 측정하였을 때에 이 혈청학적 진단법이 환자진단에 얼마나 유용한지를 평가하였다. 1984년 1월부터 1986년 1월까지 주로 신경학적 증상을 나타낸 환자 355명에서 혈청 및 뇌척수액을 검사하였다. 면역효소측정법에 사용한 항원은 돼지에 자연감염된 유구낭미충의 낭액이며 단백질 농도 2.5µg/ml로 희석하여 사용하였고, 혈청은 1:100으로 희석하여, 뇌척수액은 희석하지 않고 반응시켰고 Peroxidase-Conjugated Antihuman IgG goat serum(Cappel 회사제품)을 1:5,000으로 사용하여 혈청 및 뇌척수액내 유구낭미충 특이 IgG 항체를 흡광도로 표시하였다. 흡광도 0.18 또는 그 이상을 양성으로 판정하였다. 그 결과를 요약하면 다음과 같다.

1. 대상자 355명중 신경외과 수술 및 병리학적 소견으로 확진된 뇌낭미충증 환자 26명, 피하결절 생검에서 낭미충증을 진단하였고 뇌전산화 단층촬영으로 확진한 환자 24명, 뇌전산화 단층촬영으로 확진한 21명등 71명에서 면역효소측정법에 의한 특이 IgG항체가 양성자는 64명으로 민감도는 90.1%이었다. 그 중 혈청의 검사에 의한 민감도는 77.5%, 뇌척수액 검사에 의한 민감도는 83.1%로서 뇌척수액 검사가 더 민감한 소견이었다. 뇌낭미충증으로 확진된 환자중 위음성자는 특이 IgG 항체가 대단히 낮은 예가 대부분이었다.

2. 대상자 355명중 뇌낭미충증 이외의 질환으로 확진된 환자는 52명으로서 그중 7례는 신경외과 수술 및 병리학적 소견에 근거하여 기타 질환으로 확진된 예이며 45례는 세균학적, 방사선학적 소견등을 근거로 기타 질환으로 확진된 예이었다. 이들 중 뇌낭미충 특이항체 검사에서 음성을 보인 예는 46례로서 이 검사의 특이도는 88.5%이었다. 혈청 및 뇌척수액검사에 의한 특이도는 각각 94.2%이었다. 위양성반응을 보인 예 중에서 혈청 및 뇌척수액에서 모두 양성인 예는 없었다.

3. 혈청내 특이 IgG 항체 검사에 의한 기타 기생충감염자에서의 교차반응의 정도는 다음과 같았다. 무구조충증 18례중 2례, 스파르가눔증 20례중 2례, 폐흡충증 56례중 1례, 간흡충증 15례중 1례, 간질(肝絛)증 1례중 1례등이 교차반응을 나타내었다. 뇌척수액내 특이 IgG 항체 검사에 의한 교차반응을 뇌폐흡충증 환자 9례 중에는 없었으나 뇌스파르가눔증 환자 10례중 2례는 교차반응을 보였다.

뇌낭미충증으로 확진된 71례중 폐흡충항원에 대해 교차반응을 보인 예는 없었으나 스파르가눔 항원에 대해서는 혈청으로 검사했을 경우 6례, 뇌척수액의 경우 11례에서 교차반응을 나타내었다.

4. 뇌압상승이 있는 뇌낭미충증환자 예에서 뇌실조영술이나 뇌실부막강 단락술 도중 얻은 측뇌실 뇌척수액으로 낭미충 특이 IgG 항체를 측정하면 측뇌실에 병변이 있지 않는 한 음성 또는 낮은 양성범위의 흡광도를 보이고 있었다.

5. 포도낭미충증 환자 4례중 혈청검사로는 4례중 3례가, 뇌척수액검사로는 검사한 3례 모두가 양성반응을 보였다.

이상의 결과는 혈청 및 뇌척수액내 특이 IgG 항체를 면역효소 측정법으로 측정하는 혈청학적 진단법이 뇌낭미충증 환자의 감별진단에 매우 유용함을 보이고 있다.