

A-7

Yerba Mate(*IlexParaguariensis*)가 사염화탄소에 의해 유발된 랫트의 간손상에 미치는 영향

경북대학교 : 장승희*, 엘리아스 게브루, 아사눌레자, 최명진, 이승진, 박승춘

Hepatoprotective Effect of Yerba Mate (*IlexParaguariensis*) Extract against Carbontetrachloride-Induced Liver Damage In Rats

College of Veterinary Medicine, Kyungpook National University

Seung-Hee Jang*, Elias Gebru, Md. Ahsanur Reza, Myung-Jin Choi, Seung-Jin Lee and Seung-Chun Park

Introduction

Yerba mate tea, an infusion made from the leaves of the tree *Ilex Paraguariensis*, is a widely consumed non-alcoholic beverage in South America which is gaining rapid introduction into the world market, either as tea itself or as ingredient in formulated foods or dietary supplements. The scientific literature has been reporting the health benefits of Mate tea, which include hypocholesterolemic, anti-obesity, hepatoprotective, diuretic, antioxidant, and protective effects of the cardiovascular system and DNA oxidation. This study investigated the protective effect of Yerba Mate (*Ilex Paraguariensis*) extract against carbon tetrachloride (CCl₄)-induced liver damage in rats.

Materials and Methods

○ Materials

Yerba mate from commercial sources (Establecimiento Las Marias, Argentina) was freshly prepared into a mate infusion (50 g of herb per liter of 70% ethanol at 100°C). Then, it was concentrated at 80°C in a rotary evaporator to a final volume of 3:10 of the initial volume. Sprague Dawley rats (body weight 120-150 g) aged 6 wks were divided into 5 groups : Normal group, CCl₄ group, Yerba Mate 200 mg/kg+ CCl₄ ,Yerba Mate 400 mg/kg + CCl₄, and silymarin 200 mg/kg + CCl₄ as a positive control.

○ Methods

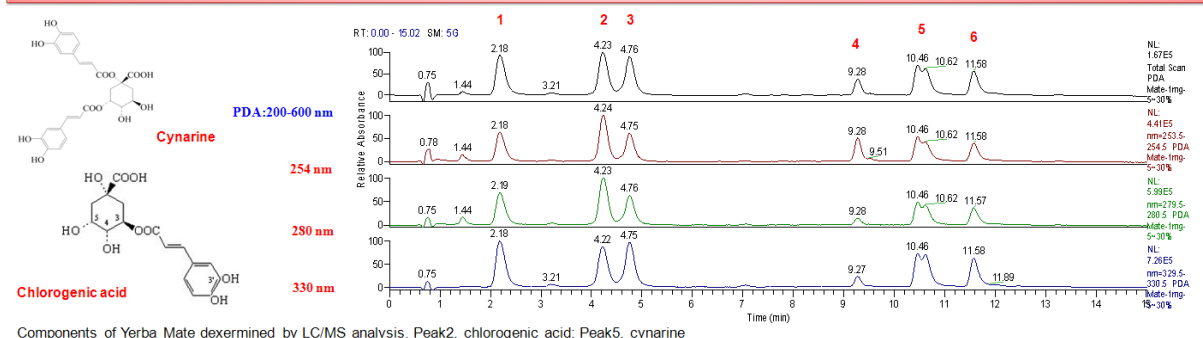
Hepatotoxicity was assessed by measuring serum GGT, ALP, ALT and AST by using auto serum analyzer (Thermo Electron, Santa Cruz, CA). SOD, GSH, and GSH-Px were determined by a commercial kit (Randox Laboratories Ltd., Antrim, UK). Liver tissues were collected from the same lobe and fixed in 10% neutral buffered formalin solution. Liver tissue was dehydrated and embedded in paraffin. Sections were stained using haematoxylin and eosin for light microscopic observations. Data were presented as mean ± SD. A one way analysis of variance (ANOVA) was performed to analyze the differences among groups.

.....
*주저자 연락처 (Corresponding author) : 장승희 E-mail : hqtop@nate.com Tel : 010-4533-7261

Results

A significant reduction in serum levels of GTT, ALP, ALT and AST was observed in CCl₄-treated rats, implying increased oxidative damage to the liver. However, rats treated with CCl₄ plus Yerba mate (200 and 400 mg/kg) and Silymarin 200 mg/kg had lower level of these enzymes compared to the CCl₄ group. Yerba mate-treated rats had also a higher level of the hepatic antioxidant enzymes (SOD, GSH and GPx) compared to CCl₄-treated group. Histopathological evaluation of liver showed the loss of hepatocytes, fatty changes, swelling and extensive necrosis of hepatocytes in centrilobular regions of the CCl₄-treated rats. However these changes were ameliorated by Yerba Mate at both 200 and 400 mg/kg concentrations and by 200 mg/kg silymarin.

Representative liquid chromatography/mass spectrometry (LC-MS) plots (right) and detected compounds (left) in yerba mate extracts



Effect of yerba mate on GGT, ALP, ALT and AST activity in serum of rats.

Group	GGT(U/L)	ALP(U/L)	ALT(U/L)	AST(U/L)
control	5.77 ± 0.66 *	40.15 ± 4.23 *	34.22 ± 4.22 *	111.12 ± 17.54 *
CCl ₄	6.30 ± 0.87 ^a	53.19 ± 6.56 ^a	171.28 ± 32.38 ^a	297.89 ± 42.78 ^a
CCl ₄ +silymarin	5.97 ± 1.00 *	41.87 ± 4.11 *	66.97 ± 30.14 ^{a*}	263.78 ± 54.70 ^{a*}
CCl ₄ +mate (200 mg/kg)	6.04 ± 0.96 *	47.19 ± 6.81 *	133.30 ± 41.89 ^{a*}	302.88 ± 29.87 ^a
CCl ₄ +mate (400 mg/kg)	5.65 ± 1.70 *	42.56 ± 6.28 *	104.31 ± 20.86 ^{a*}	202.27 ± 51.21 ^{a*}

* different from CCl₄ group ($P < 0.05$), ^adifferent from control ($P < 0.05$)

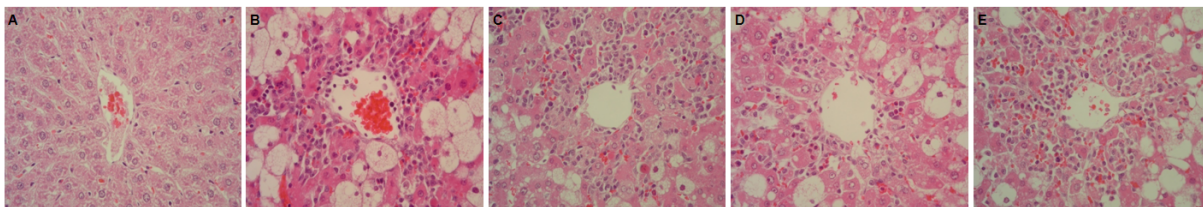
Effect of yerba mate on liver SOD, GSH and GSH-Px in CCl₄-intoxicated rats.

Group	SOD (%)	GSH (u mol NADPH/min/ug protein)	GPX(m mol NADPH/min/ug protein)
control	47.2 ± 1.6 *	62.3 ± 9.9 *	2.09 ± 0.18 *
CCl ₄	16.9 ± 3.5 ^a	12.1 ± 3.3 ^a	0.14 ± 0.12 ^a
CCl ₄ +silymarin	33.6 ± 3.3 *	39.8 ± 9.7 ^{a*}	1.87 ± 0.52 *
CCl ₄ +mate (200 mg/kg)	28.4 ± 6.5 ^a	82.5 ± 13.8 *	1.12 ± 0.43 ^{a*}
CCl ₄ +mate (400 mg/kg)	47.2 ± 8.4 *	81.3 ± 3.9 *	1.85 ± 0.23 *

All values are means ± SD (n = 6).

* different from CCl₄ group ($P < 0.05$), ^adifferent from control ($P < 0.05$)

Effect of yerba mate on histological structure of the liver



(A) Hepatic tissue of control (B) CCl₄- (C), silymarin (200 mg/kg) and CCl₄- (D), yerba mate (200 mg/kg) and CCl₄- (E), and yerba mate (400 mg/kg) and CCl₄ treated rats. Original magnification 400x