

Application of Advanced Functional Maps to the Radiation Treatment Plan for Biological Clinical Target Volumes

Ji-Yeon Park^{*†}, Jeong-Woo Lee[‡], Won-Gyun Jung^{*†}, Kook-Jin Ahn[§], Tae-Suk Suh^{*†}
^{*}Department of Biomedical Engineering, [†]Research Institute of the Biomedical Engineering, The Catholic University of Korea, [‡]Department of Radiation Oncology, Konkuk University Medical Center, Konkuk University, [§]Department of Radiology, Seoul St. Mary's Hospital, The Catholic University of Korea
E-mail: jjfortunity@catholic.ac.kr

Keyword : Multi-parametric maps, rCBV maps, ADC maps, Biological clinical target volume, Image registration

서론

Anatomical images including computerized tomography (CT) and T1-weighted magnetic resonance (T1-MR) images have been generally used to determine target volumes in radiation treatment plan (RTP). As only conventional images were referenced, tumors have tendency not to be enhanced by administrating agents depending on the tumor grade and patients [1]. Recent advanced MR images, however, could guide physiologically and pathologically significant tumor characteristics. Furthermore, if the multi-functional images are employed, errors from using only one type of image will be complemented and distinct biological parameters can be applied as histological activity index. In this study, biological clinical target volumes (bCTVs) considered vascularity and cellularity can be determined based on multi-functional parametric maps using the in-house software for image registration and analysis.

재료 및 방법

The developed program consists of two primary tabs for image registration between different anatomical image sets (CT and T1/T2 - MR images)

and between anatomical images (T1/T2-MR images) and functional maps (rCBV and the ADC maps). The software provides several functions such as calculation of ADC values, evaluation of correlations between functional parameters, and export of post-processed CT images including determined bCTVs.

The outline to acquire the bCTVs is summarized in Fig.1 and image sets of a glioblastoma patient were tested [2]. Registration was implemented three - step process including mutual information, affine transform and non-rigid demon registration. The registration accuracy was evaluated using the overlap ratio of segmented bone and contour transition. After overlapped bCTVs from two functional maps were determined, the voxels corresponding lower values than average ADC (avg. ADC) + standard deviations (SDs) with higher vascularity were resolved as malignant sub-volumes.

결과 및 고찰

The registered T1-MR image was shown in adjustable transparency with reference CT image as in Fig. 2. The registration accuracy by the bone segmentation and contour evaluation was 74% and average 2.5 mm error, respectively. As shown in table of Fig. 2, Avg. ADC and SDs were calculated based

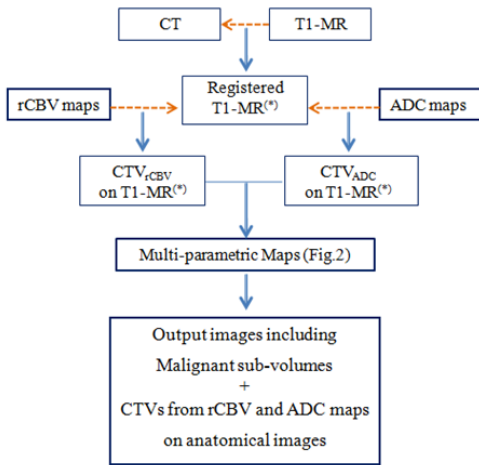


Fig.1 The outline to obtain the biological clinical target volumes based on analysis rCBV maps and ADC maps. (The dotted line means the image registration and direction.)

on interest regions. Using the quantitative ADC values, tumor malignancy was evaluated and volumes showing the high probability of malignant cells were extracted. The correlation between vascularity and cellularity on the same voxels in overlapped CTVs was shown in multi-functional parametric maps. Using the image registration, obtained biological CTVs and malignant sub-volumes are remarked on CT images for preliminary biological RTP.

Because extracted malignant sub-volumes are based on the two types of functional maps, some errors caused by using only one type of functional images could be decreased. As the determination of the CTVs, insufficient and obscure regions would be complementary with other images reflected different aspects. However, verification of correlations between obtained parameters and actual tumor status is required. If more detailed categorized levels to evaluate tumor malignancy and advanced technical registration for functional images are achieved, usefulness and reliability of application of functional maps or multi-modal images to RTP would be improved. Moreover, feasibility of using multi-functional parametric maps would be required to

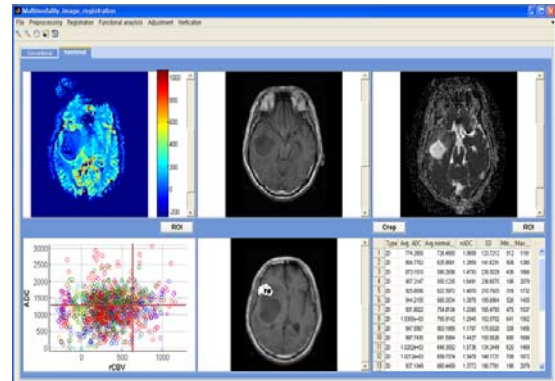


Fig.2 Functional tab of in-house software for analysis and mapping of multi-functional parameters using functional maps.

evaluate for biological RTP.

결론

Using the developed software, rCBV and ADC maps were analyzed and bCTVs can be resolved considering vascularity and cellularity. In result, the bCTVs are exported on conventional images for biological RTP using image registration. Based on the multi-functional parametric maps of overlapped tumor regions, malignant sub-volumes can be determined. Multi-functional parametric maps would contribute to the detection of physiological and pathological tumor characteristics which are not be found in conventional images. They would reflect individual tumor biological characteristics to RTP for local tumor control.

참고 문헌

1. Fan GG, Deng QL, Wu ZH, Guo QY. Usefulness of diffusion/perfusion-weighted MRI in patients with non-enhancing supratentorial brain gliomas: a valuable tool to predict tumour grading? Br J Radiol 2006; 79: 652-8.
2. Henson JW, Gaviani P, Gonzalez RG. MRI in treatment of adult gliomas. Lancet Oncol 2005; 6: 6167-75