

Arterio-Venous Malformation : Its Anatomical & Physiological Control with Free Flap Transfer

Department of Plastic & Reconstructive Surgery, Yonsei University College of Medicine, SEOUL, KOREA

Kwan Chul Tark, MD, PhD, FACS

Vascular anomalies are classified into two major categories : hemangioma and malformations based on endothelial characteristics. It is clinically important to separate the vascular malformations into "low flow" or "high flow" categories. Among the high flow vascular malformations, arteriovenous malformation (AVM) is one of the most troublesome lesion to manage.

Embryological studies suggest that AVMs consist of macrofistulae and microfistulae. Although the blood flow is marked and rapid throughout the AVM, oxygenation is reduced distally because much blood flow is wasted through these short circuits of fistulae.

Interference with this flow by means of conventional treatment modalities such as resection, embolization or ligation of the feeding vessel, or sclerosis has been said to cause additional arteriovenous shunts and ischemia to open that were not present or functional previously so as to maintain a physiological balance of hemodynamics. Therefore "Complete Control" or "Cure" of the AVM may rest not only with removal of the symptomatic area but also with the replacement or addition of normally vascularized tissue to obliterate these ischemic environments.

In 18 patients with AVM - 6 patients with pure high flow AVM and 12 patients with combined AVM with low flow malformation on the head and extremity, the author transfer-

red radial forearm free flap after near total excision of the lesion, and followed up the patients from 2 years to 14 years grossly and histologically.

All 6 patients with pure high flow AVM were cured without recurrence. The part of the residual lesion next to the transferred free flap disappeared, and the remaining discoloration also vanished grossly. A 4 months and several years postoperative histological study of the residual lesion using Victorian blue staining showed a typical preoperative finding of the AVM-an intermingling of thick-walled vessels with abundant elastic fibers and thin-walled vessels without elastic fiber-had undergone an alteration resulting in the disappearance of the thick-walled vessels leaving only homogeneous thin-walled vasculature. In 12 patients with combined AVM with low flow malformation, anatomical replacement of the disfigured skin was main objective of the free flap transfer.

Highly vascularized free flap transfers impact on the anatomical and physiological control of AVM by blocking the vicious cycle of ischemia.

In this presentation diagnosis and treatment algorithm for vascular malformation, indication and techniques for free flap transfer, postop management and long term clinical and histologic follow up results will be reviewed.

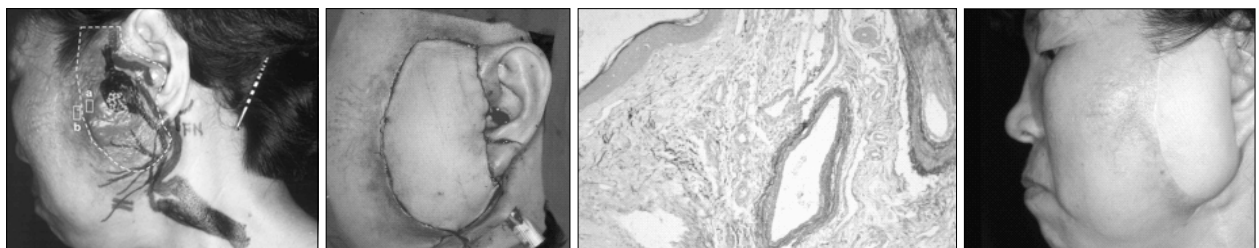


Fig. 1. AVM on left cheek. (Lt) Preop shows typical AVM. The lesion was near totally excised and forearm flap was transferred. (Rt) Postop 2 years. The cure of AVM was confirmed by histologic follow up.