

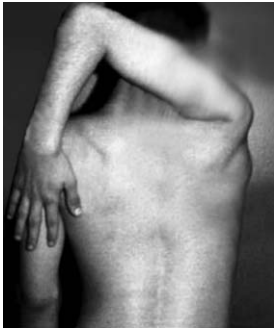Multidirectional Instability

조선대학교 의과대학병원

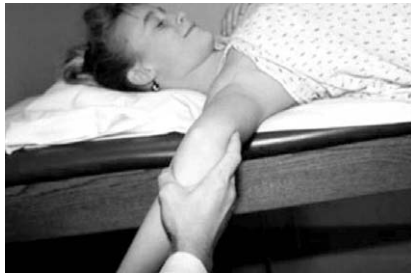문영래

■ Terminology

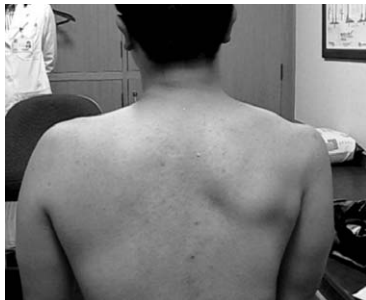- Atraumatic “instability”



- Physiologic Laxity

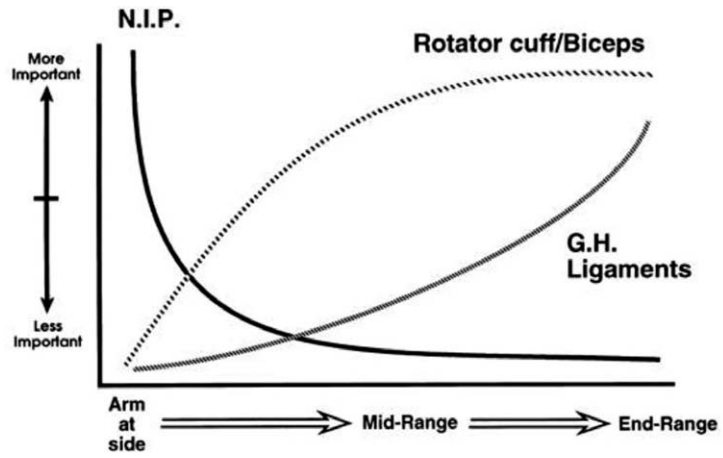


- Voluntary instability



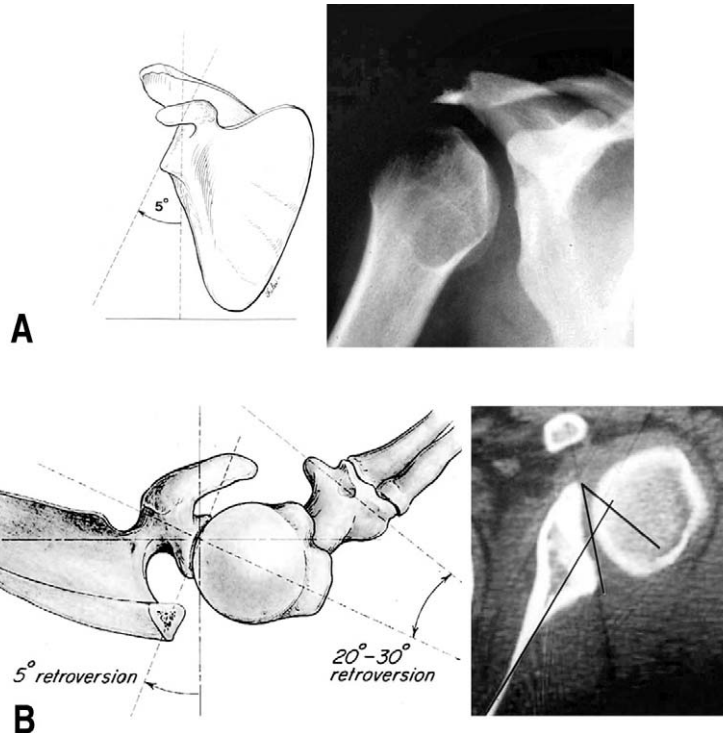
- Trauma and laxity and instability

■ Biomechanical Definition⁴⁾



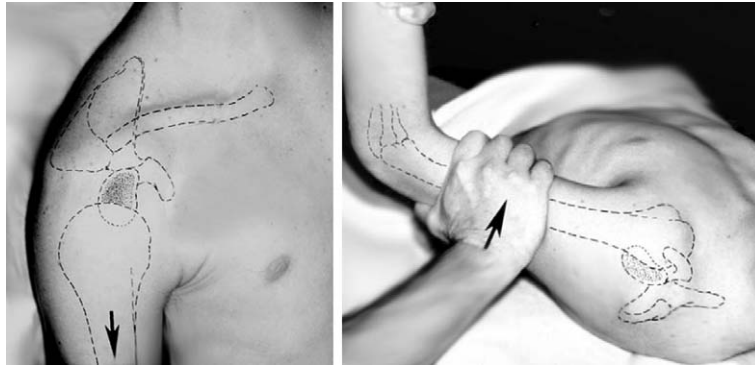■ Pathoanatomy^{6,10)}

- 관절면

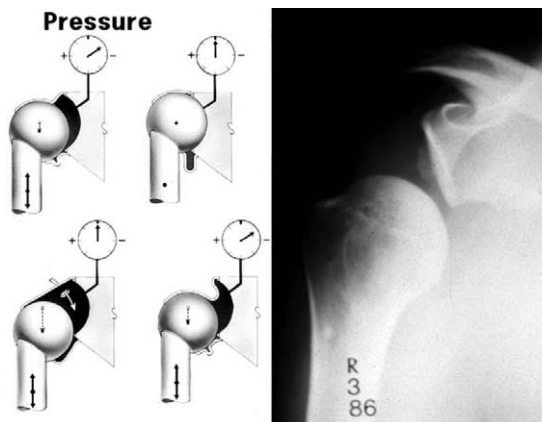


제 4차 대한건·주관절학회 연수강좌

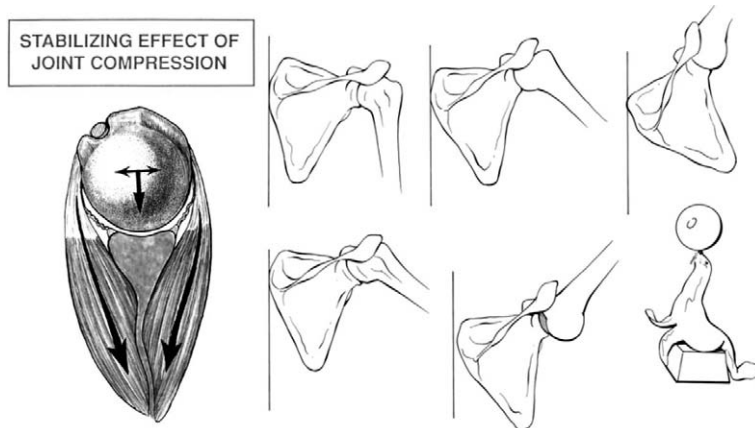
- Static ligamentous factors

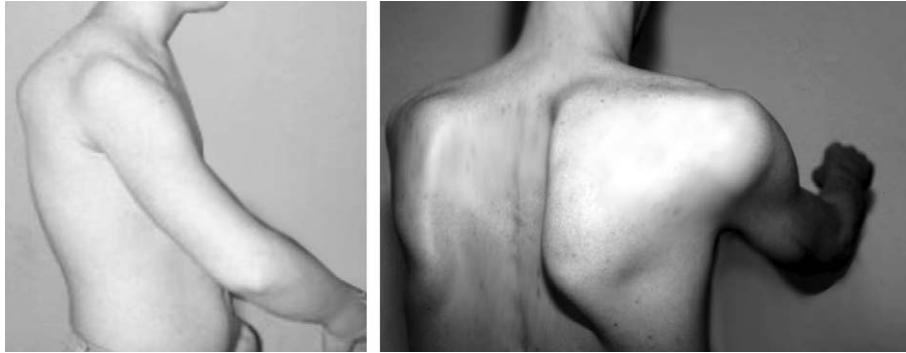


- Sulcus sign의 의미



- Dynamic Factors¹³⁾

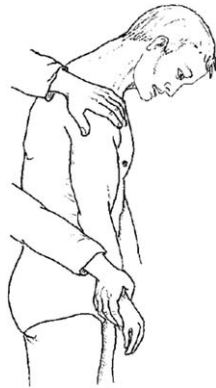



■ Physical Examination Finding

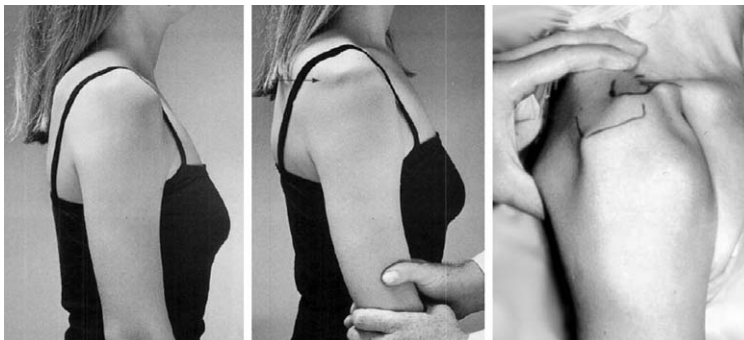
• Rowe Test

- Anterior and inferior instability check



• Sulcus sign의 의미

- 0도 위치에서의 sulcus sign



90도 위치에서의 sulcus sign (Inferior apprehension test)

■ Direction of Instability

- Translation testing
- Correlate with symptoms
- Voluntarism
- Intraop vs office

■ Treatment

1. Conservative

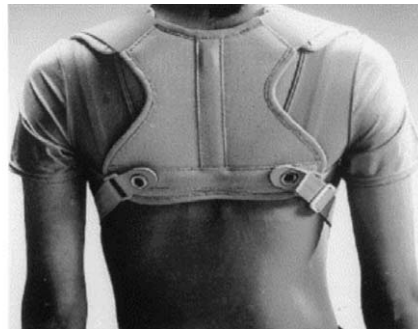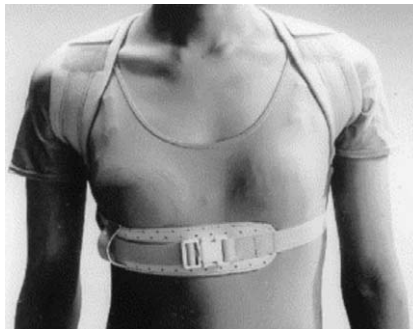
- Physiotherapy

2. Surgery

- A. Open
- B. Arthroscopic

Conservative Treatment⁸⁾

■ Orthosis



Physiotherapy⁹⁾

1. Rotator Cuff Strengthening.
2. Axioscapular muscle conditioning

• Rationale

- Most young, active patients are not happy if they can't do their sport
- Even with surgery some cannot return to sports like throwing & swimming
- Activity and life-style modifications necessary for satisfaction
- People become "stiffer" with age...

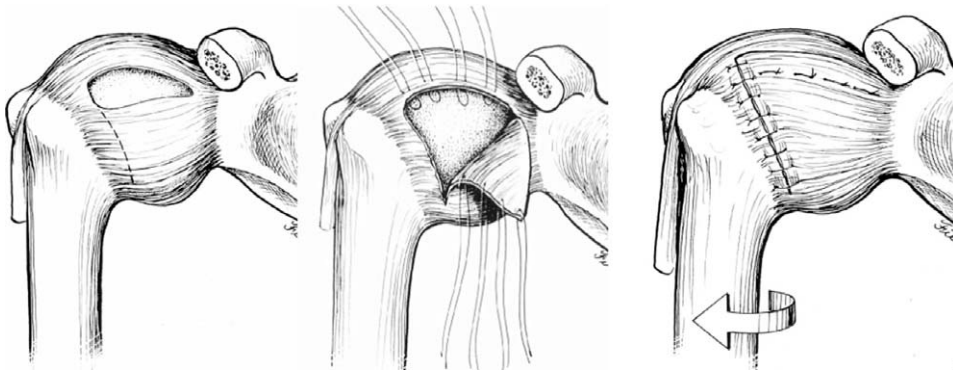
Surgical Treatment

■ Surgical Goals

- Address capsular laxity
- Focus on inferior capsule

■ Surgical Options

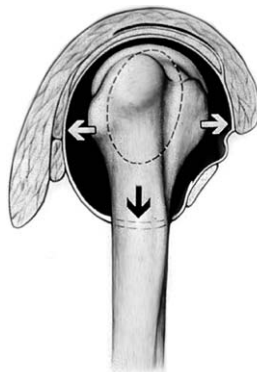
- Open
 - Rotator interval closure
 - Capsular Shift
 - Anterior or posterior
- Arthroscopic
 - Thermal shrinkage
 - Suture imbrications
- Open rotator interval closure¹⁴⁾



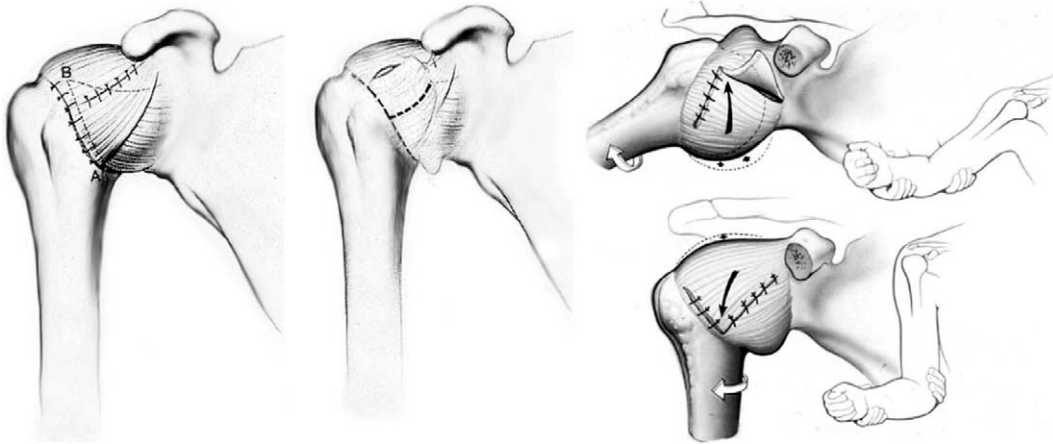
• Open Capsular shift³⁾

- Indications

Symptomatic multidirectional instability



- Technique



- Advantages

- Proven reliability
- Capsular tightening
- Early motion
- Less technical expertise

- Disadvantages

- Subscapularis takedown
- Greater risk of motion loss
- Difficult return to overhead sports

Arthroscopic Treatment

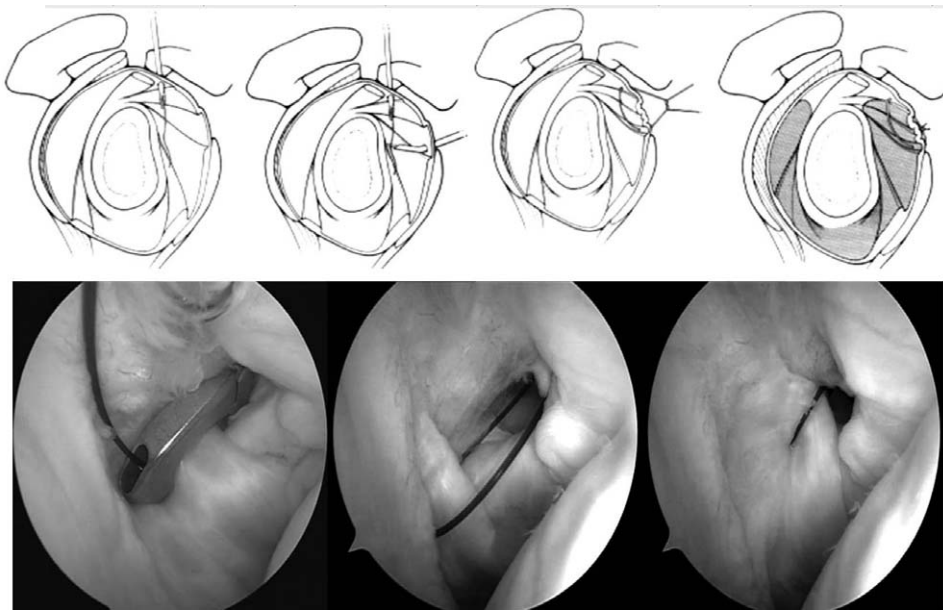
- Goals of Surgery

- ↓ Capsule volume
- Anterior
- Capsular pouch
- Rotator interval
- Posterior

• Arthroscopic imbrication^{1,2,9,11)}

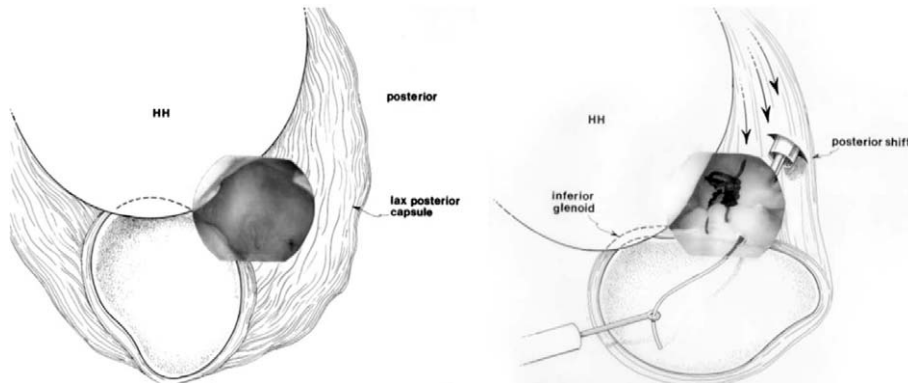
- Rotator interval closure
- Anterior capsular shift
- Posterior capsular shift

- Rotator interval closure⁷⁾



- Anterior capsular shift

- Posterior capsular shift



• Thermal Capsular Shrinkage^{12,15)}

- Indications

Technical expertise

Informed pt. willing to take extra risk of failure

Microinstability

Athlete

- Rationale

Denature and shorten collagen with application of heat

Wall, O' Brien, Warren, JSES '99

Tissue shrinkage related to temperature

Histologic denaturing of collagen

Wall, O' Brien, Warren, JSES '99

Max shrink 15% before material property changes

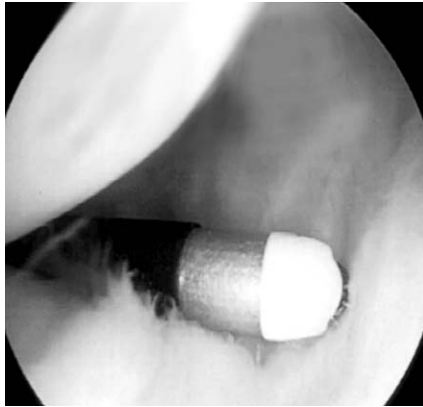Shrink must be protected

- Technique

Standard portals

High anterior

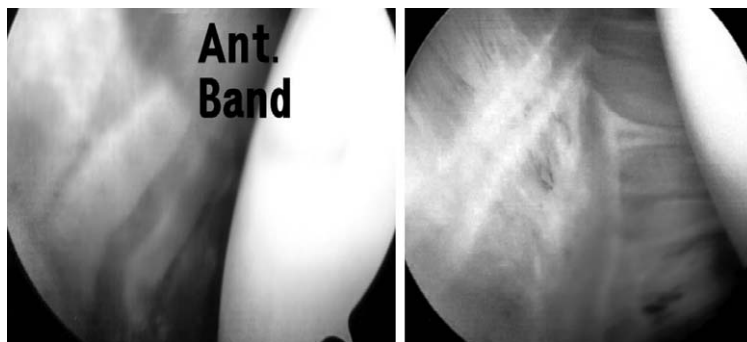
Sweep MGHL and anterior band of IGHL



- Two posterior portals

Probe parallel to scope

- Sweep anterior to posterior



- Advantages

No Subscapularis Takedown

Cosmetic

Less perioperative morbidity

Shorter, possibly easier operation

- Disadvantages
 - Less reliable
 - Long term outcome
 - Complications
 - Bridges burned
- Results
 - Complications - Anecdotal
 - Recurrent instability
 - Capsular loss
 - Postoperative frozen shoulder
 - Synovitis
 - Axillary neuropathy

REFERENCES

1. **Caprise PA., Jr., and Sekiya J K.:** Open and arthroscopic treatment of multidirectional instability of the shoulder. *Arthroscopy*, 22(10): 1126-31, 2006.
2. **Cicak N, Klobucar H, Bicanic G and Trsek D.:** Arthroscopic extracapsular plication to treat multidirectional instability of the shoulder. *Arthroscopy*, 21(10): 1278, 2005.
3. **Ekin A, Ozkan M, Bolukbasi S, Kanatli U, and Karci T.:** [Multidirectional shoulder instability and open surgical procedures]. *Acta Orthop Traumatol Turc*, 39 Suppl 1: 83-9, 2005.
4. **Flatow EL, and Warner JJ.:** Instability of the shoulder: complex problems and failed repairs: Part I. Relevant biomechanics, multidirectional instability, and severe glenoid loss. *Instr Course Lect*, 47: 97-112, 1998.
5. **Foster CR:** Multidirectional instability of the shoulder in the athlete. *Clin Sports Med*, 2(2): 355-68, 1983.
6. **Gohlke F:** [Biomechanics of the shoulder]. *Orthopade*, 29(10): 834-44, 2000.
7. **Harryman DT 2nd, Sidles JA, Harris SL and Matsen, FA., 3rd:** The role of the rotator interval capsule in passive motion and stability of the shoulder. *J Bone Joint Surg Am*, 74(1): 53-66, 1992.
8. **Ide J, Maeda S, Yamaga M, Morisawa K, and Takagi K:** Shoulder-strengthening exercise with an orthosis for multidirectional shoulder instability: quantitative evaluation of rotational shoulder strength before and after the exercise program. *J Shoulder Elbow Surg*, 12(4): 342-5, 2003.
9. **Kim SH; Kim HK, Sun JI, Park JS and Oh I.:** Arthroscopic capsulolabroplasty for posteroinferior multidirectional instability of the shoulder. *Am J Sports Med*, 32(3): 594-607, 2004.
10. **Lippitt S, and Matsen F.:** Mechanisms of glenohumeral joint stability. *Clin Orthop Relat Res*, (291): 20-8, 1993.
11. **Millett PJ, Clavert P, and Warner JJ.:** Arthroscopic management of anterior, posterior, and multidirectional shoulder instability: pearls and pitfalls. *Arthroscopy*, 19 Suppl 1: 86-93, 2003.
12. **Miniaci A, and McBernie J.:** Thermal capsular shrinkage for treatment of multidirectional instability of the shoulder. *J Bone Joint Surg Am*, 85-A(12): 2283-7, 2003.
13. **Warner JJ, Bowen MK; Deng X, Torzilli PA, and Warren RF.:** Effect of joint compression on inferior stability of the glenohumeral joint. *J Shoulder Elbow Surg*, 8(1): 31-6, 1999.
14. **Wirth MA, Groh GI, and Rockwood CA Jr.:** Capsulorrhaphy through an anterior approach for the

treatment of atraumatic posterior glenohumeral instability with multidirectional laxity of the shoulder. J Bone Joint Surg Am, 80(11): 1570-8, 1998.

15. **Wolf RS, and Lemak LJ.**: Thermal capsulorrhaphy in the treatment of multidirectional instability of the shoulder. J South Orthop Assoc, 11(2): 102-9, 2002.