

Four-Dimensional Computed Tomography for Gated Radiotherapy: Retrospective Image Sorting and Evaluation

*Department of Radiation Oncology, Asan Medical Center, †Department of Medical Physics, Kyonggi University

Sangwook Lim*[†], Sung Ho Park*, Geum Mun Back*, Seung Do Ahn*, Seong Soo Shin*,
Sang-Wook Lee*, Jong Hoon Kim*, Eun Kyuon Choi*, Soo Il Kwon[†]

To introduce the four-dimensional computed tomography (4DCT, Light Speed RT, General Electric, USA) scanner newly installed in our department and evaluate its feasibility for gated radiotherapy. Respiratory signal measured by real-time position management (RPM[®], Varian Medical, USA) was recorded in synchronization with the 4DCT scanner. 4DCT data were acquired in axial cine mode and sorted retrospective image based on respiratory phase. PTVs delineated from helical CT and 4DCT images were compared. The PTV delineated from conventional helical CT images was 2 cc larger than that from 4DCT images. Dose in PTV of the plan from retrospective CT was 99.3% (minimum=72.0%, maximum=106.5%) and that of helical CT plan was 95.2% (minimum=24.1%, maximum=106.4%) of prescribed dose. Comparing with DVHs of both plan, the coverage for 4CDT plan was 3.7% improved. It is expected that 4DCT could improve tumor control and reduce radiation toxicity for liver cancer.

Key words: 4DCT, Retrospective CT, Gated radiotherapy, RPM

INTRODUCTION

Organ motion caused by respiration is known to substantially affect treatment of thoracic and abdominal region. During respiration, tumors in lung and liver typically move up to 4 cm¹⁾ and large volume of normal tissue is irradiated. Therefore, a generous margin due to respiratory motion should be considered. Although respiratory target motion differs depending on the patients and the sites, conventionally planning target volume (PTV) is delineated with 1 cm margin in craniocaudal direction for the target in lung.

To take into account organ motion explicitly in treatment planning and delivery, time-resolved CT data acquisition is necessary.²⁾ Recently, a 4-slice CT scanner became available and allowed for four-dimensional (4D) CT or respiration-correlated CT scans to be performed.³⁾ This study introduces the 4DCT (Light Speed RT, General Electric, USA) newly installed in our department and evaluates its feasibility for gated radiotherapy.

MATERIAL AND METHODS

4DCT data were acquired by 4-slice CT scanner in an axial cine mode and a helical mode, respectively. A liver cancer patient was selected, whose target was located in right upper lobe of liver. The patient was instructed to breathe freely during the CT scan. Prior to CT scanning, patient's respiration cycle was monitored until it was stable. Both helical CT and 4DCT images data acquired with slice thickness of 2.5 mm.

Motion phases were recorded by real-time position management (RPM[®], Varian Medical, USA) in synchronization with the x-ray "on" signal from the CT scanner when 4DCT data were being gathered. Since respiratory signal was digitally stamped on each CT slice, it was possible to reconstruct CT slices retrospectively at several phases over respiratory cycle, yielding a

연제 발표 1: Four-Dimensional Computed Tomography for Gated Radiotherapy: Retrospective Image Sorting and Evaluation, Sangwook Lim, et al
 4D dataset. The 4DCT dataset were sorted out for 10 phases of motion in percent within the respiratory cycle by 4DCT software. As shown Fig. 1, 0% corresponds to end-inhalation and 50% to end-exhalation. In this study 30%, 40%, 50%, 60%, and 70% phases of respiration were selected for retrospective image sorting.

Both helical CT images and retrospective CT images were transported to treatment planning system (TPS). TVs were delineated from helical CT images and retrospective CT images with 1 cm PTV margin for helical CT and 0.5 cm for retrospective CT, respectively. DVHs for both plans were calculated and compared.

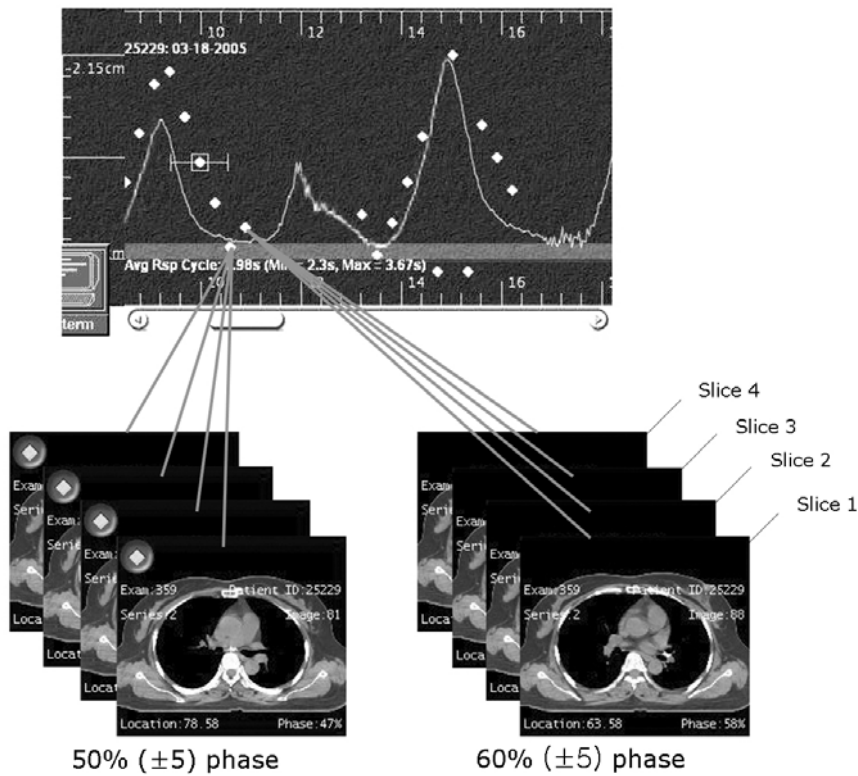


Fig. 1. 4DCT images were sorted based on each phase, which divided into 10 phase groups. The slice thickness was 2.5 cm.

RESULTS

Total number of 4DCT images were 484 slices and separated according to 10 phases in percent with $\pm 5\%$ tolerance. The average patient's respiratory cycle was measured 2.98 s (minimum=2.3 s, maximum=3.67 s). Fig. 2 shows the coronal view of 4DCT images assorted by organ positions depending on phases. Organ motion due to respiration was observed 1.5 cm in craniocaudal direction in this case by measuring the displacement of diaphragm between 0% phase (end-inhalation) and 50% phase (end-exhalation).

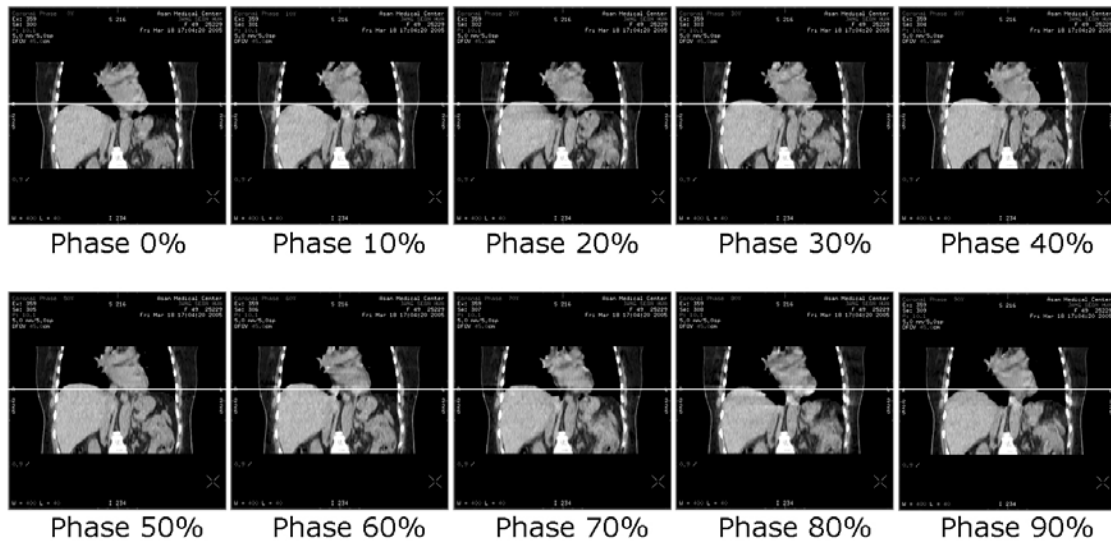


Fig. 2. Coronal view of 4DCT images sorted at different phase of respiration: it was separated into 10 positions of the diaphragm while moving as imaged with 4DCT. Motion range was measured 1.5 cm in craniocaudal direction. The 30~70% ($\pm 5\%$) phases were selected for retrospective CT.

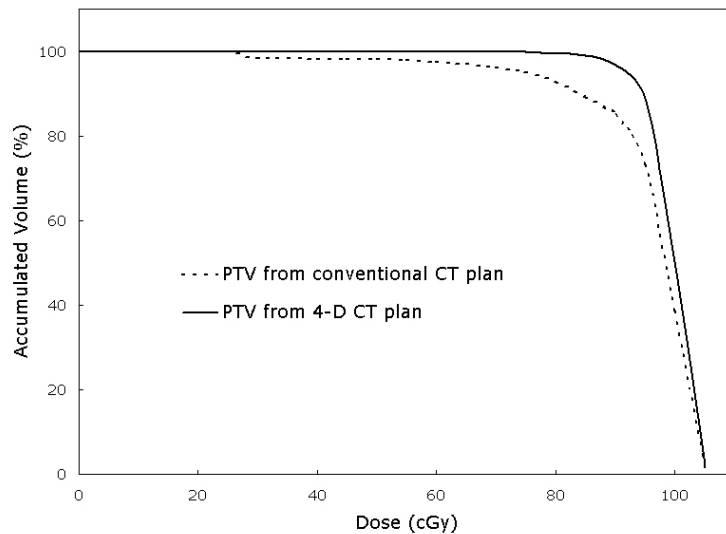


Fig. 3. Comparison of DVH, calculated from conventional CT plan and 4DCT plan for the same patient: The maximum accumulated volumes for each plan were normalized to 100%. Comparing to the conventional method, the DVH was calculated 3.7% larger.

The PTV delineated from conventional helical CT images was 2 cc larger than that from 4DCT images. Dose in PTV of the plan from retrospective CT was 99.3% (minimum=72.0%, maximum=106.5%) and that of helical CT plan was 95.2% (minimum=24.1%, maximum=106.4%) of prescribed dose. Comparing with DVHs of both plan, the coverage for 4CDT plan was 3.7% improved in Fig. 3.

CONCLUSION

Conventionally, slow scanning techniques has been used to obtain CT data including target motion and routine margin has been considered for moving target. 4DCT and RPM[®] enabled gated treatment planning and delivery, which could effectively improve target coverage. The minimum doses in PTV for helical CT plan and 4DCT plan were calculated to 24.1% and 72.0% of prescribed dose, respectively. It shows that the uniformities was significantly improved using 4CDT.

We have to compromise over treatment time and accuracy, when we select phases for retrospective CT. Backprojected densities could be smeared out in moving direction according to the tolerance of the respiratory phase. Since respiratory cycle and motion differ from patients and target location, appropriate phase and tolerance selection required.

It is expected that 4DCT could improve tumor control and reduce radiation toxicity for liver cancer.

REFERENCES

1. Mageras GS, Pevsner A, Yorke ED, et al: Measurement of lung tumor motion using respiration-correlated CT. *Int J Radiat Oncol Biol Phys* 60:933-41 (2004)
2. Rietzel E, Pan T, Chen GTY: Four-dimensional computed tomography: Image formation and clinical protocol. *Med Phys* 32:874-89 (2005)
3. Underberg RWM, largerwaard FJ, Cuijpers JP, et al: Four-dimensional CT scans for treatment planning in stereotactic radiotherapy for stage I lung cancer. *Int J Radiat Oncol Biol Phys* 60:1283-90 (2004)