

Arthroscopic Anatomy of the Hip

Yerl-Bo Sung, M.D.

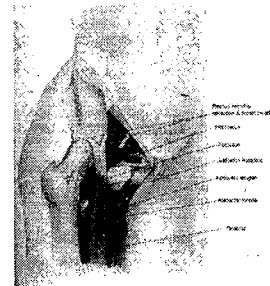
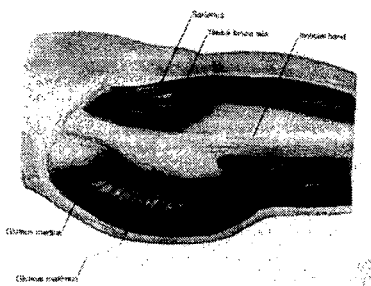
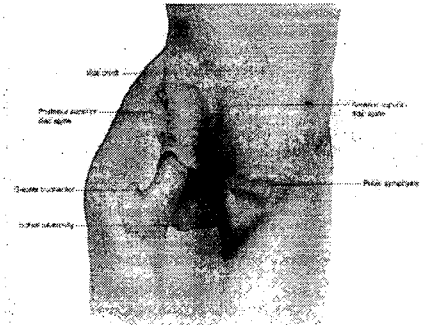
Department of Orthopaedic Surgery
Inje University Sang-Gye Paik Hospital

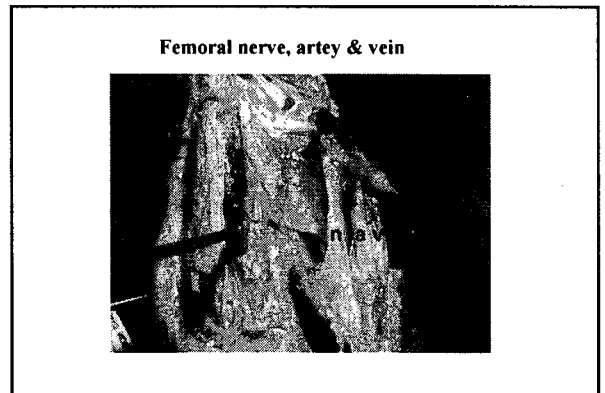
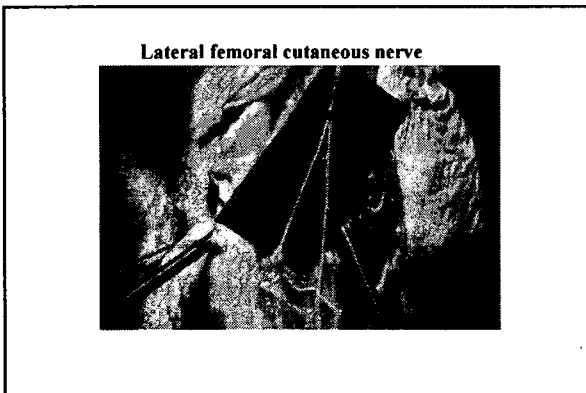

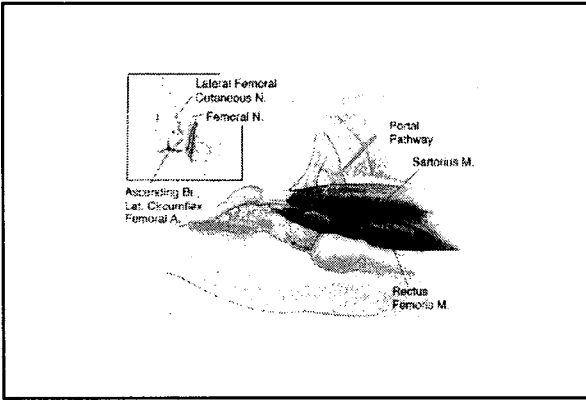
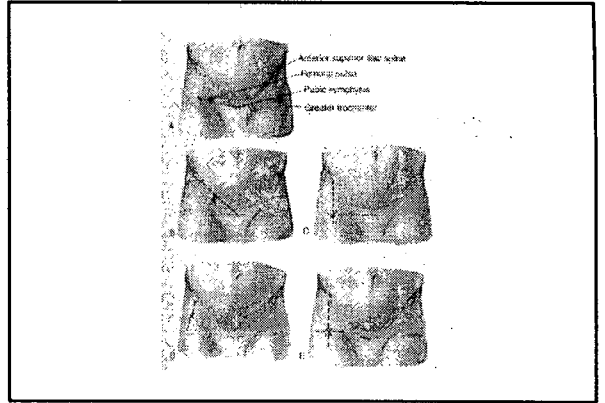
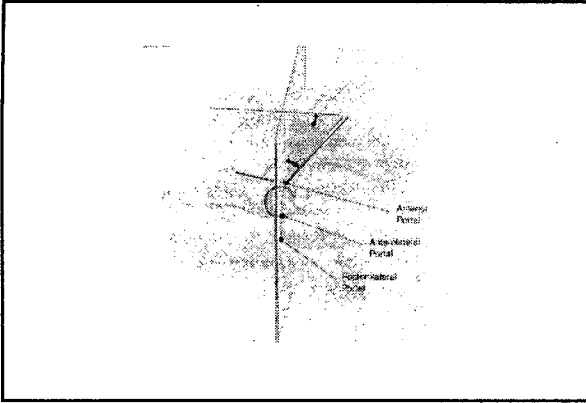
1. Gross Anatomy

2. Portal Anatomy

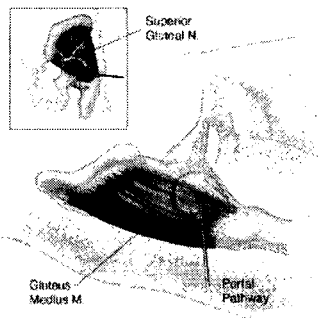
3. Arthroscopic Anatomy

1. Gross Anatomy

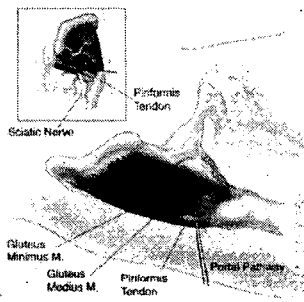
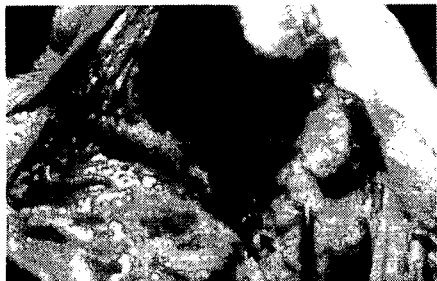


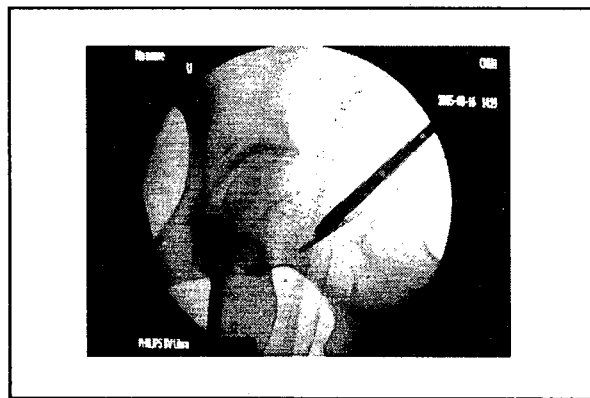
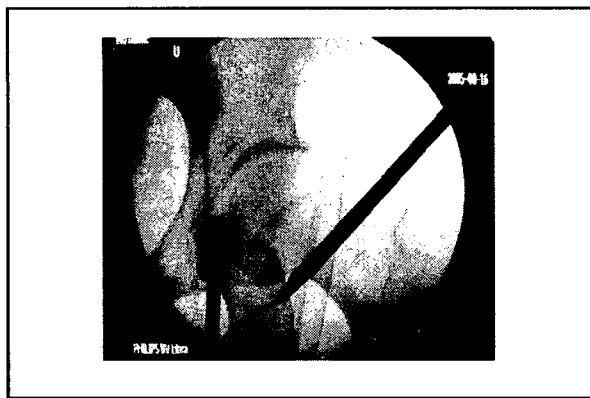
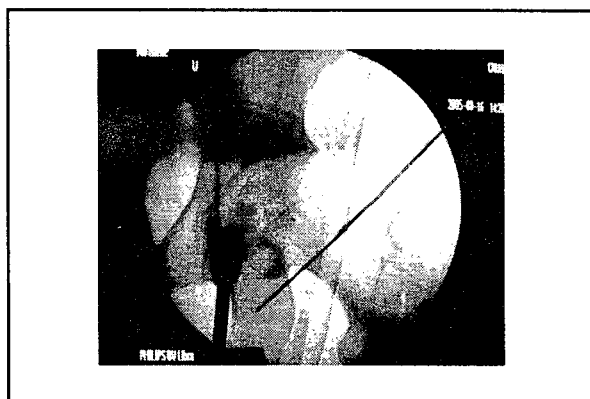
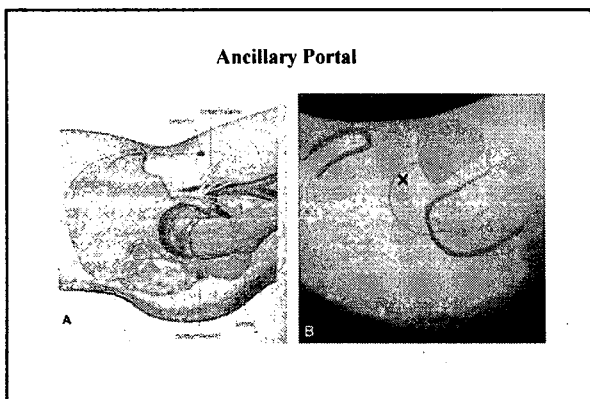

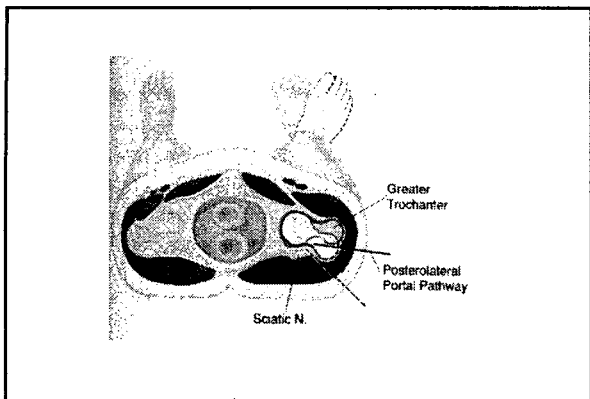


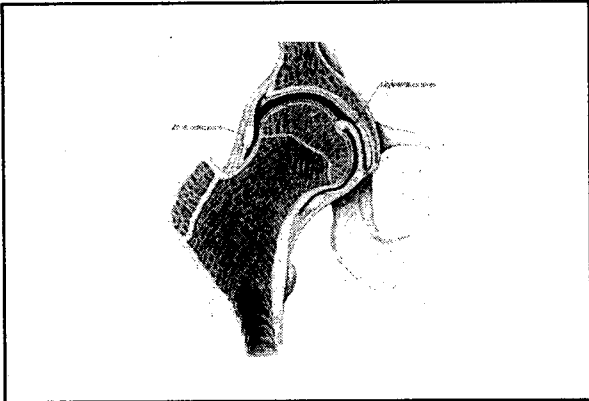
**Lateral circumflex artery: Ascending branch
Terminal branch**



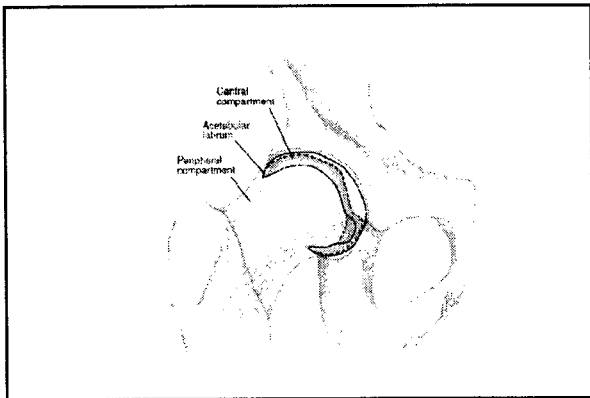
Superior gluteal nerve



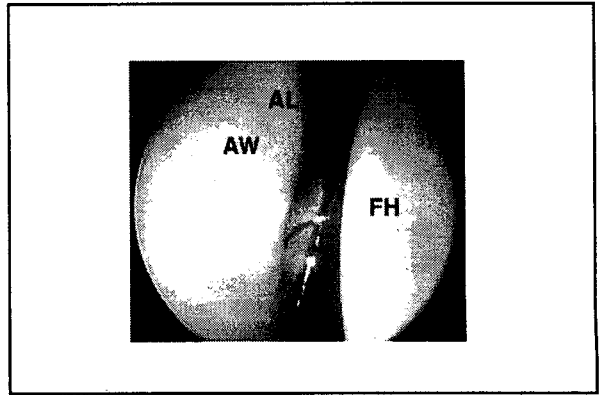
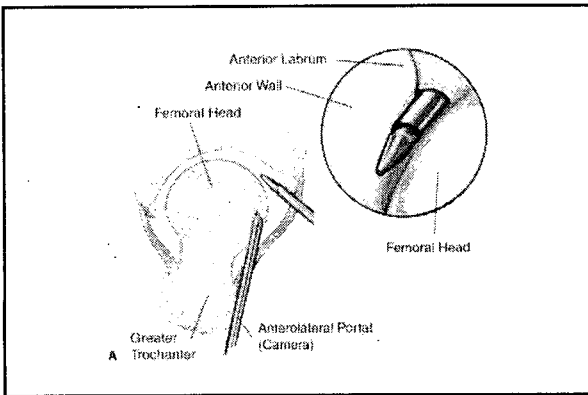


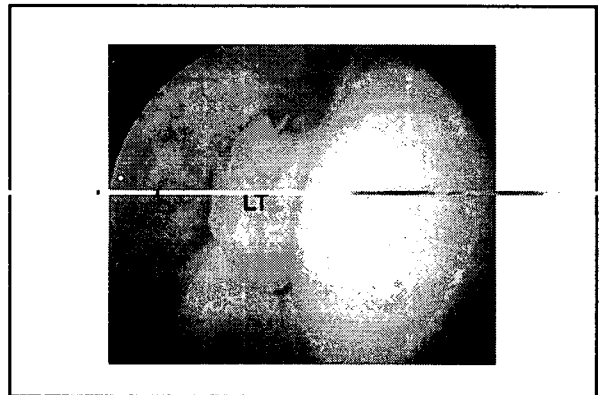
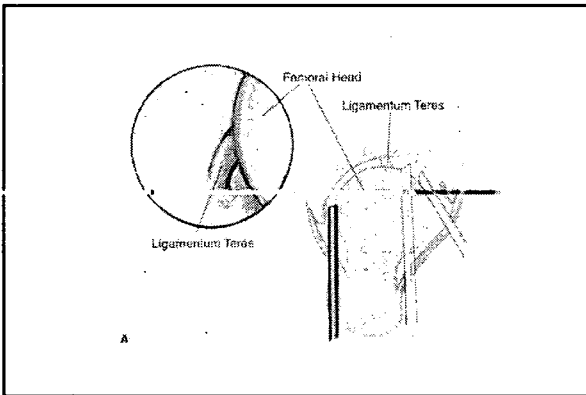
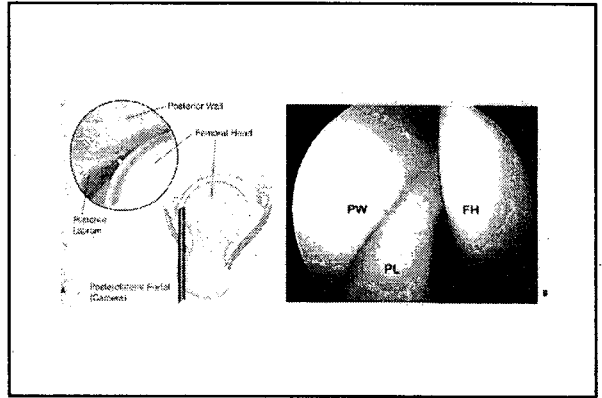
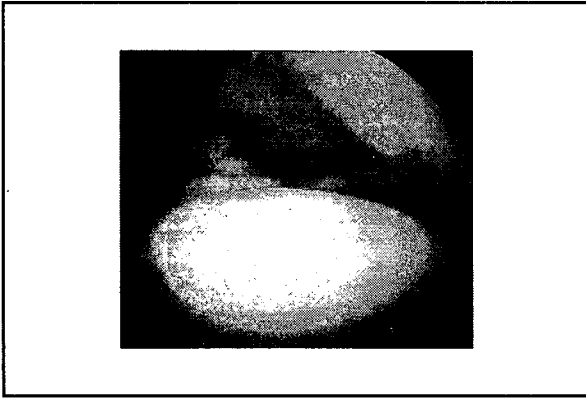
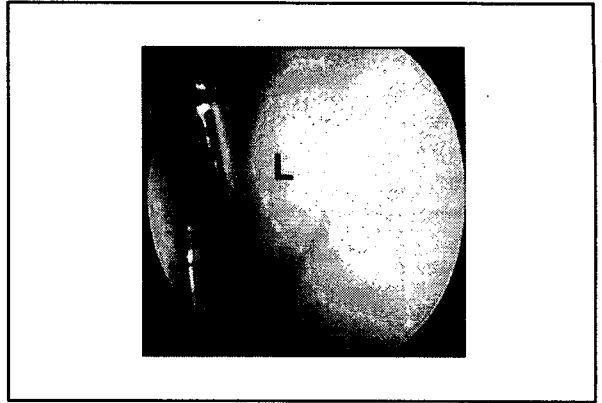
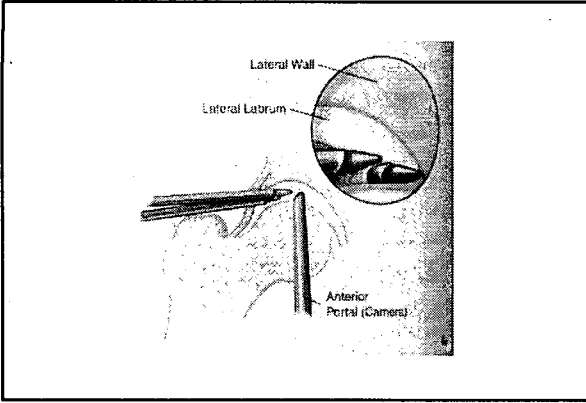


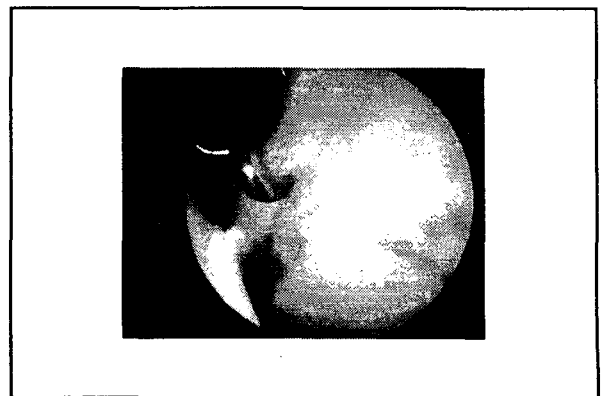

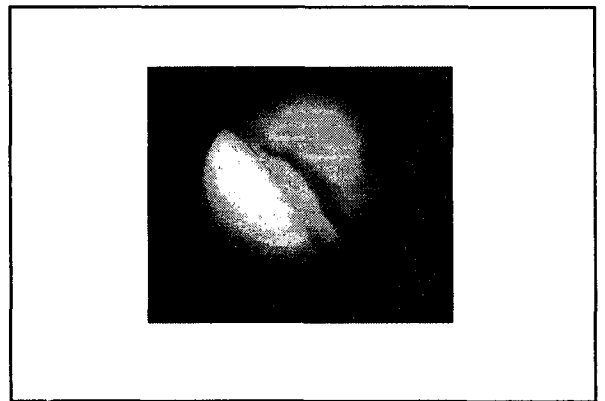
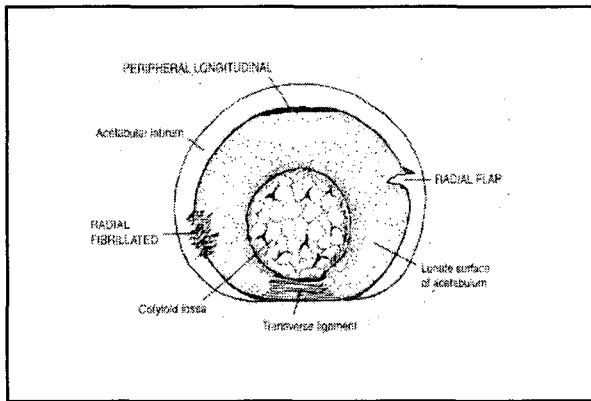
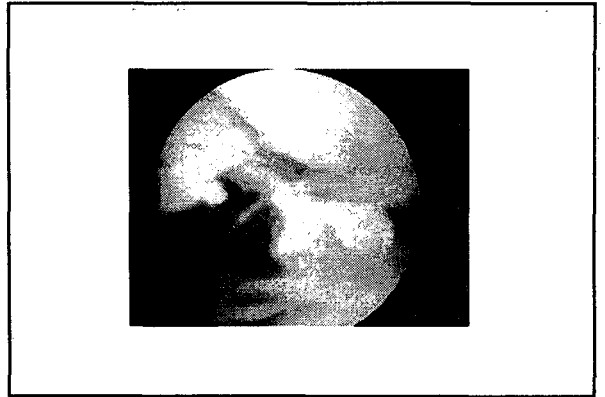
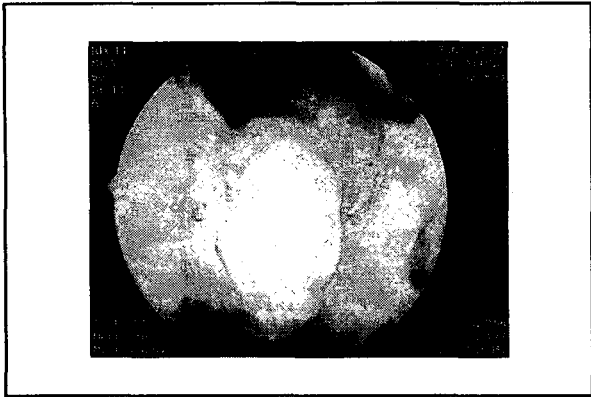
3. Arthroscopic Anatomy



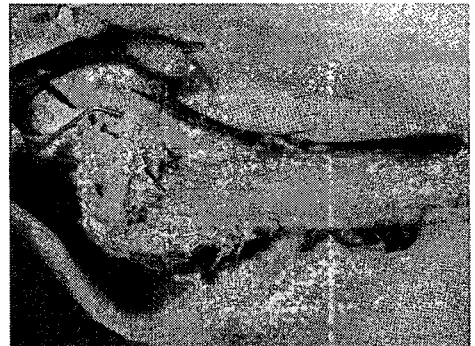
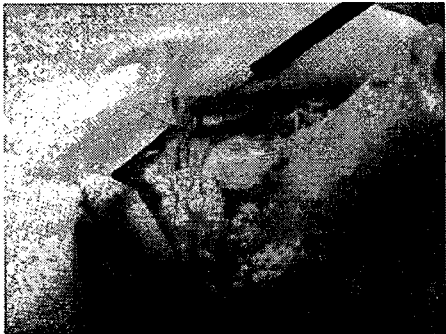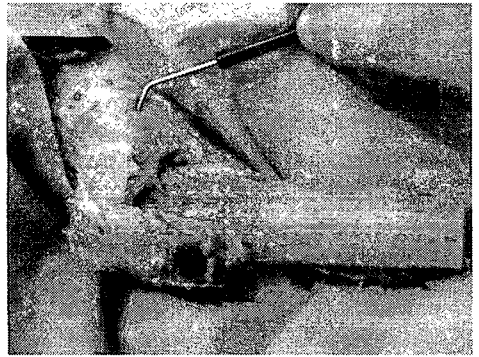
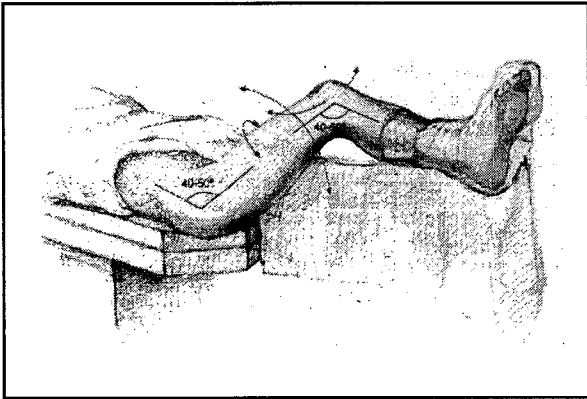
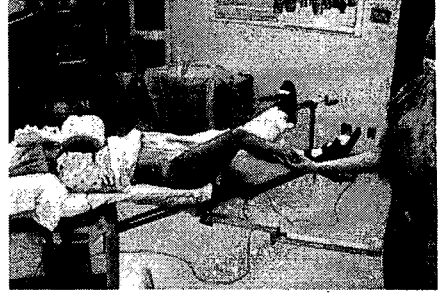Central Compartment

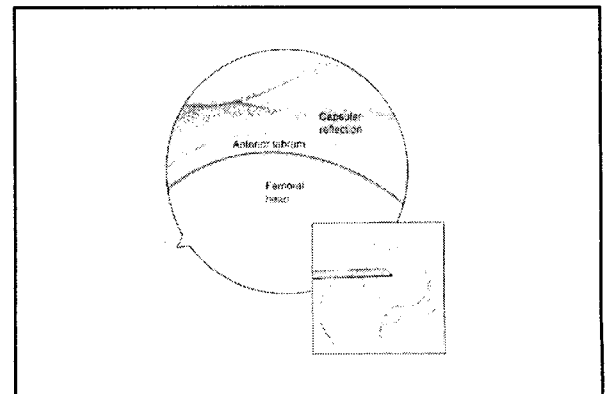
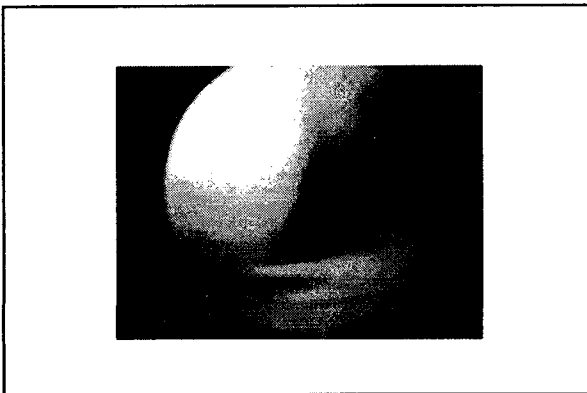
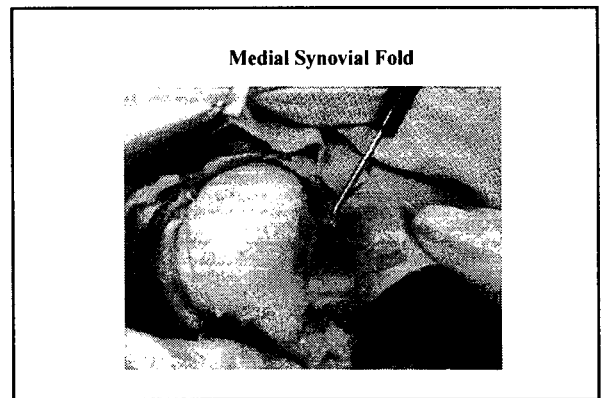
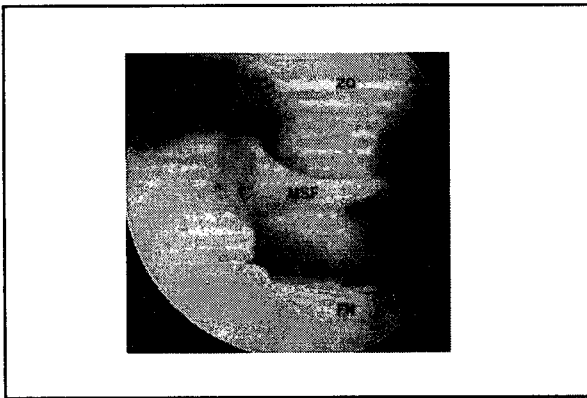
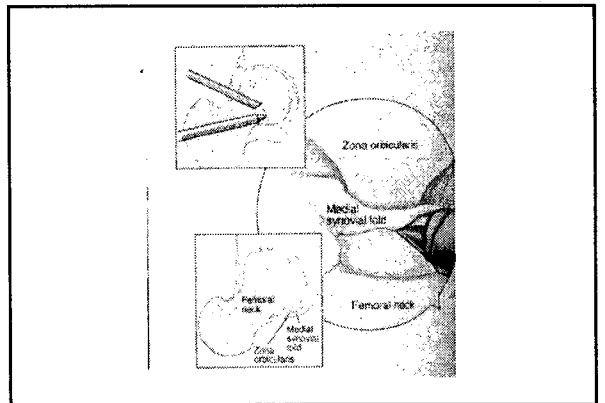
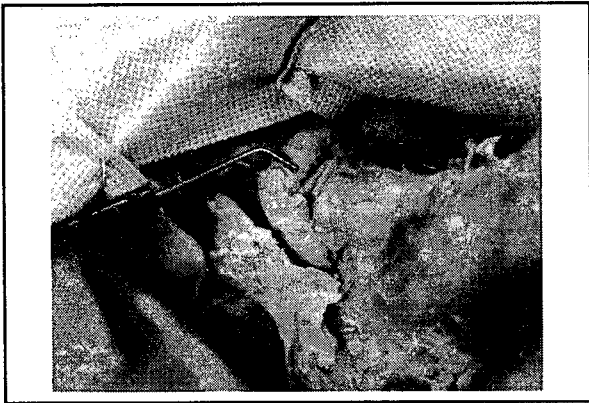

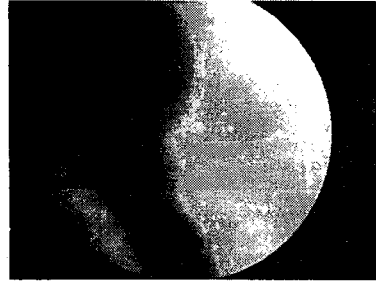
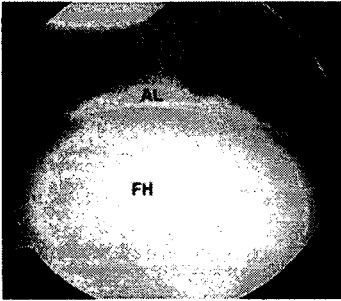




Peripheral Compartment
: without traction







Thanks for attention!