

Bennett Lesion

문영래

조선의대 정형외과학교실

■ Definition

: An ossification of the posteroinferior glenoid in the proximity of the posterior band of the inferior glenohumeral ligament complex.

: A unique posterior shoulder abnormality occurring in throwing athletes.

■ Etiology^{2-4,7}

1. Excessive pull on the posterior capsule^{6,7}
2. Posterior impingement during cocking^{6,7}
3. Traction phenomenon during deceleration
4. Sequelae of a capsular tear and an avulsion injury.^{1,5}

■ Associated lesion

1. Posterior labral tears
2. Posterior undersurface rotator cuff tears
3. Subluxation.

■ Diagnosis

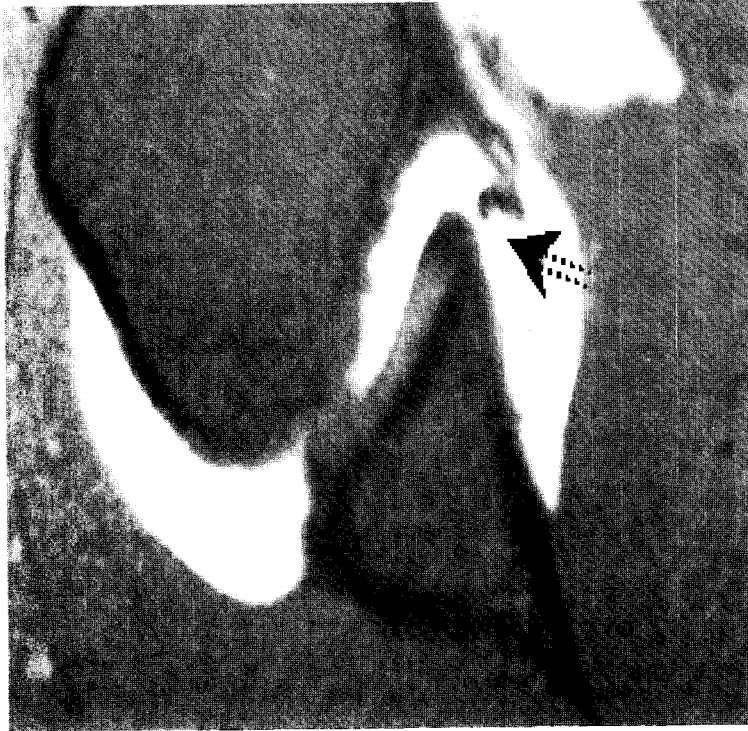
1. Plain films

A. Bennett view

- Accomplished with the arm abducted and externally rotated and with 5° of cephalad angulation of the X-ray beam²⁻⁴

B. Stryker notch views

2. Magnetic resonance imaging



3. CT-arthrography

■ Differential diagnosis

1. The posterior glenoid fractures
2. The calcification or ossification of the posterior labrum or capsule

■ Clinical symptoms

- The mechanism for clinical symptoms is also poorly understood
 1. The shoulder pain during the cocking phase, follow-through phase, or both
 2. Often secondary to the associated intraarticular abnormalities
 3. The referred pain to the deltoid

■ Treatment

1. Conservative
 - Usual method
2. Surgical removal of lesion
 - Variable results^{1,7}

<참고문헌>

1. Barnes DA, Tullos HS. An analysis of 100 symptomatic baseball players. *Am J Sports Med* 62: 62-7, 1978.
2. Bennett GE. Elbow and shoulder lesions of baseball players. *Am J Surg* 98: 484-92, 1959.
3. Bennett GE. Shoulder and elbow lesions distinctive of baseball players. *Ann Surg* 126: 107-10, 1947.
4. Bennett GE. Shoulder and elbow lesions of the professional baseball pitcher. *JAMA* 117: 510-3, 1941.
5. Ferrari JD, Ferrari DA, Coumas J, Pappas AM. Posterior ossification of the shoulder: the Bennett lesion. Etiology, diagnosis, and treatment. *Am J Sports Med* 222: 171-5; discussion 175-6, 1994
6. Fronck J, Warren RF, Bowen M. Posterior subluxation of the glenohumeral joint. *J Bone Joint Surg Am* 71 2:205-16, 1989.
7. Lombardo SJ, Jobe FW, Kerlan RK, Carter VS, Shields CL, Jr. Posterior shoulder lesions in throwing athletes. *Am J Sports Med* 53: 106-10, 1977.