B5 – 4

Study of Convolution Kernel on the Clinical CT Method for Evaluating Density of Thin Cortical Bone.

Shinichi Wada, Kazuhide Hayama, Makoto Tsuchimochi

Dept. of Oral and Maxillofac. Radiol.,The Nippon Dental University, School of Dentistry at Niigata.

INTRODUCTION:

In the assessment of osteoporosis the determination of bone density using clinical CT has mainly developed for the measurements of trabecular bone not for cortical bone. One of the reasons is caused by an inaccuracy for assessing cortical width and density by CT scanner. But it became obvious that trabecular bone density measurements do not predict future fracture risk sufficiently. The measurements of cortical bone density also are expected to play an important role for assessing overall bone strength. In recent studies the determination of cortical density is reported to be limited to the bones with a thickness higher than 2mm[1-3] caused by spatial resolution of CT scanner. We have studied to establish a new method for accurate measurements of the density of thin cortical bone less than 2mm thickness using a clinical CT. On the method convolution kernel used in reconstruction was considered to be an important parameter. The purpose of this study was to test how the CT convolution kernel affect this method.

METHOD:

The CT image profile function I(x) is denoted by the object function O(x) and normalized Line Spread Function L(x) using: $I(x)=O(x) * L(x)$[3,4]. * is a convolution of O (x) and L (x). Measurements of the LSF were made with a CT scanner (Xforce, Toshiba). Normalized L (x) were obtained with six different reconstruction kernels - four soft tissue mode kernels and two bone window mode kernels. The area of the integral of the object function was assumed equal to the area of the integral of the image profile function [5]. Numerical integration and measurements using a new tissue equivalent phantom containing a wedge-shaped cortical bone substitute were performed to confirm this assumption. In order to estimate the width of the image spread, computer simulations were performed under various conditions of cortical width and density of object function with use of L (x) of respective reconstruction kernels . The results of computer simulations were compared with the measurements made on the phantom.

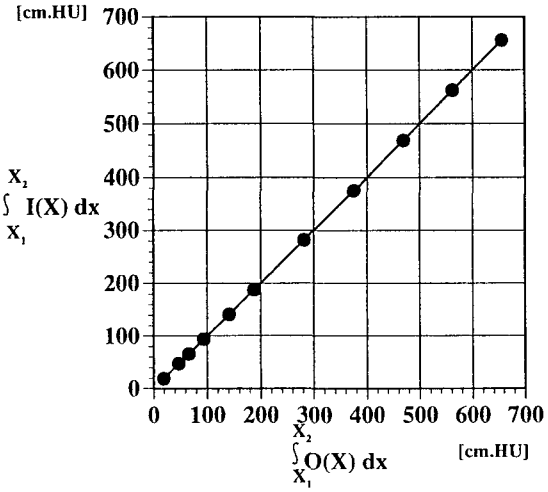

Fig.1. Integrals of object function and image profile function in the range from X_1 to X_2 were confirmed equal on a clinical CT.

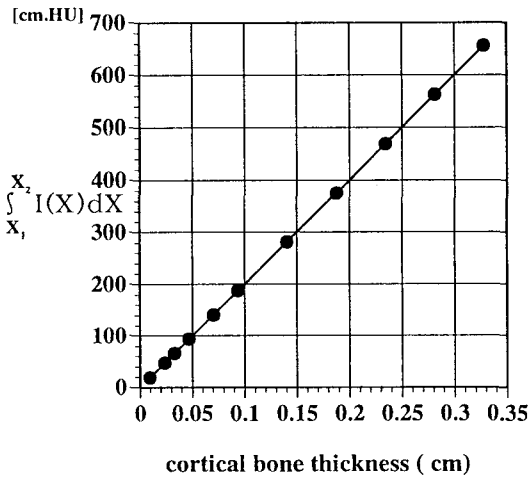

Fig.2 Relationships between cortical bone thickness and integrals of image profile. Lineality was maintained down to the thickness of 0.1mm .

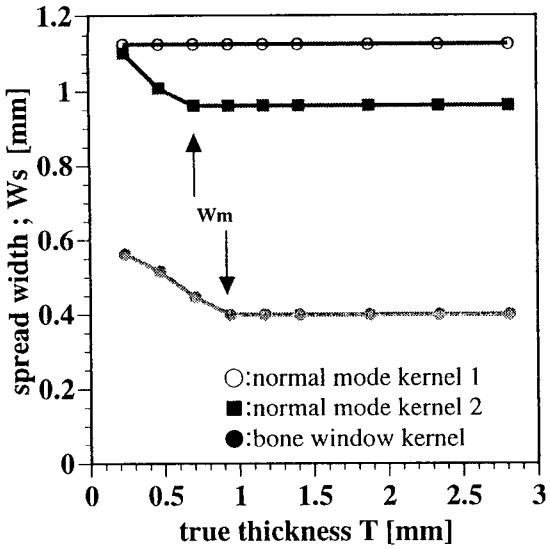

Fig. 3. Relationships between spread width Ws and true cortical thickness T. Ws showed constant values peculiar to convolution kernel over the thickness Wm. Ws was independent from the density of cortical bone or the tissue density adjacent to cortex.On the normal mode kernel 1, Ws was constant down to a cortical thickness of <0.4mm.

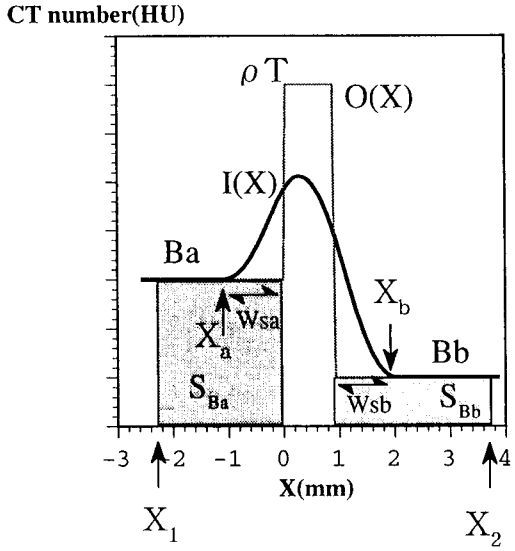

O(X);Object function
I(X) ;Image profile function
T ; True thickness of cortical bone
ρ ; Density of cortical bone
ρT ;cortical mass thickness
Ba ; density of tissue **a** adjacent to cortex
Bb ; density of tissue **b** adjacent to cortex
Wsa ;spread width to a
Wsb ;spread width to b
Wsa=Wsb= constant when LSF has no undershooting (Fig.1)

T=Xb-Xa-2Wsa

$$\int_{X_1}^{X_2} I(X)\,dX = \int_{X_1}^{X_2} O(X)\,dX$$

$$\int_{X_1}^{X_2} I(X)\,dX - S_{Ba} - S_{Bb} = \rho T$$

Fig.4. Cortical mass thickness and cortical bone density can be calculated from Xa, Xb, Ba, Bb, Ws and integration of I(X). This method suggests accurate measurement of the density of thin cortical bone less than 2mm thickness using a clinical CT .

RESULTS:

The numerical integrations of the object function and image profile function agreed(fig.1). Phantom measurements showed good agreement with the computer simulations. The results were consistent to a cortical width of 0.1mm(fig.2). Computer simulations showed(Fig.3) that the image-spread width at the background level was constant regardless of the cortical width or density above the minimum width Wm which is peculiar to L(x). The estimated Wm of respective reconstruction kernel were in the range of < 0.4mm to 0.9mm . The smallest Wm was obtained for the normal mode kernel of which L (x) was approximated by a Gaussian distribution The reconstruction kernels which had undershoot in the tail of the distribution L(X) showed relatively large Wm.

Based on these results an algorithm was developed which enable to measure cortical mass

thickness, cortical width and cortical density down to a width of <0.4mm (Fig.4).

CONCLUSIONS:

We suggest a new accurate method to measure cortical bone density using clinical CT. On this method the reconstruction kernel is essential and required not to have undershoot in the tale of LSF. Some of normal mode kernels were demonstrated to be suitable for this method on the clinical CT scanner we used.

REFERENCES:

1) Hangartner TN, Gilsanz V:Evaluation of Cortical bone by computed tomography, J Bone Miner Res 11:1518-1525,1996.
2)Newman DL, Dougherty G et al: Limitations of clinical CT in assessing cortical thickness and density, Phys.Med.Biol, 43:619-626,1998
3) Prevrhal S, Engelke K, Kalender WA: Accuracy limits for the determination of cortical width and density:the influence of object size and CT imaging parameters,Phys.Med.Biol, 44:751-764,1999
4) Wada S, Takahashi K, Katada T, Tsuchimochi M: An analytical method for precise measurements of cortical bone thickness using CT image . CAR'98-Lemke HU, Vannier MW, Inamura K & Farman A(Editors), ELSEVIER, PP.63-67, 1998.
5) Wada S, Sato R, Tsuchimochi M:Study of cortical mass thickness using CT image, Jpn J Med Phys, Supp.60, 25,1999.